

+ Evidence in focus

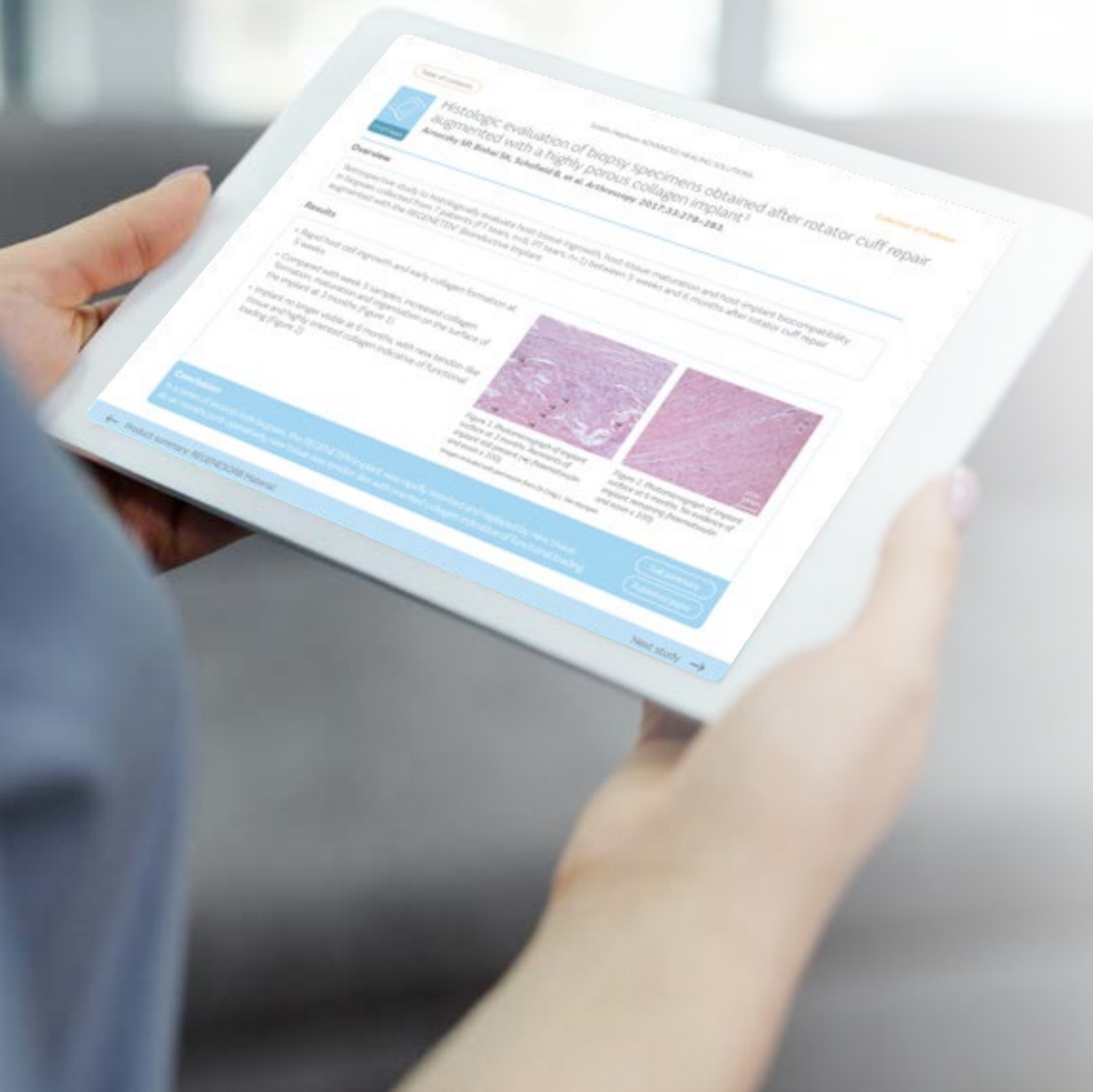Collection of evidence

ADVANCED HEALING SOLUTIONS Biological Portfolio

- REGENETEN[◇] Bioinductive Implant
- HEALICOIL[◇] REGENESORB[◇] Suture Anchor
- HEALICOIL KNOTLESS Suture Anchor
- REGENESORB Material

February 2024

Smith+Nephew



Overview

This evidence collection summarises the clinical evidence on the **ADVANCED HEALING SOLUTIONS** portfolio

Redefining biological healing for rotator cuff repair

Click the products below to view the product summary

Navigation tips

Interactivity has been included throughout the collection to aid navigation

[Table of contents](#)

will take you to a table of evidence, organised by product. Key evidence is represented in **light blue** and supporting evidence in **brown**



arrows at the bottom of each page will take you to the previous or subsequent page, as indicated

[Full summary](#)

will take you to the **Evidence in focus** full summary of the relevant study

[Published paper](#)

will take you to the journal website where the study is published

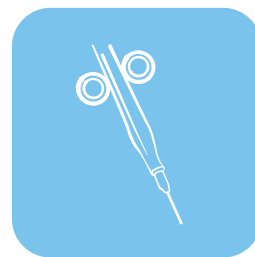Key to icons




Imaging
outcomes



Patient
outcomes



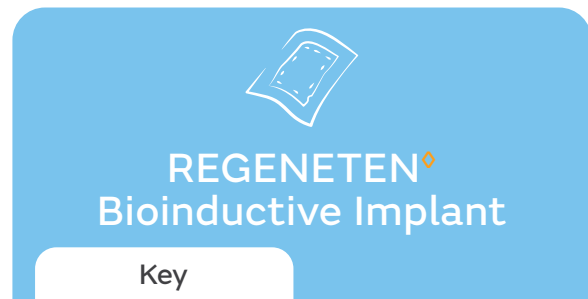Biopsy



Biomechanical

Table of contents

→ Click on the arrow by the study reference to view the study overview.



Author	Key finding				
Key evidence					
Arnoczky SP, et al. 2017¹	REGENETEN Implant was rapidly absorbed and replaced by tendon-like tissue within 6 months			✓	
Bokor DJ, et al. 2016²	REGENETEN Implant promoted rapid and sustained healing of partial-thickness (PT) rotator cuff tears	✓	✓		
Bokor DJ, et al. 2019³	No decline in tendon integrity between 2 and 5 years post-operatively for most patients treated with the REGENETEN Implant	✓	✓		
Bushnell BD, et al. 2021⁴	REGENETEN Implant led to significantly improved pain, shoulder function and HRQoL at 3, 6 and 12 months in patients with PT rotator cuff tears		✓		
Camacho-Chacon JA, et al. 2022⁵	REGENETEN Implant led to high healing rates and implant integration with full-thickness (FT) and PT rotator cuff tears	✓	✓	✓	
Ruiz Ibán M, et al. 2023⁶	Use of REGENETEN Implant to augment repair of medium and large FT rotator cuff tears resulted in significantly lower re-tear rates compared with repair alone	✓	✓		
Schlegel TF, et al. 2020⁷	REGENETEN Implant reduced the size of PT rotator cuff tears by over 50% in all tear locations	✓	✓		
Thon SG, et al. 2019⁸	REGENETEN Implant led to tissue induction and high rates of tendon healing in large and massive rotator cuff tears	✓	✓		

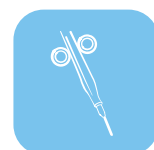Key to icons



Imaging outcomes



Patient outcomes



Biopsy



Biomechanical

→ FT tears

→ FT+PT tears

→ Not applicable (NA)

→ PT tears

→ Pre-clinical





Table of contents

→ Click on the **arrow** by the study reference to view the study overview.



REGENETEN[®]
Bioinductive Implant

Supporting

Author	Key finding				
Supporting evidence					
Bokor DJ, et al. 2015⁹	REGENETEN Implant maintained repair integrity in FT rotator cuff tears	✓	✓		
Bushnell BD, et al. 2022¹⁰	REGENETEN Implant used in the repair of medium-sized and large FT rotator cuff tears led to low re-tear rates at 24 months	✓	✓		
Dai AZ, et al. 2020¹¹	REGENETEN Implant led to significant post-operative improvements in pain and function in an independent case series of PT rotator cuff tears	✓	✓		
McIntyre L, et al. 2019¹²	REGENETEN Implant led to clinically meaningful improvements in pain and function for patients with PT and FT rotator cuff tears		✓		
McIntyre LF, et al. 2021¹³	REGENETEN Implant resulted in significant improvements in pain, shoulder function and HRQoL at 12 months in FT rotator cuff tears		✓		

Key to icons



Imaging outcomes



Patient outcomes



Biopsy



Biomechanical

→ FT tears

→ FT+PT tears

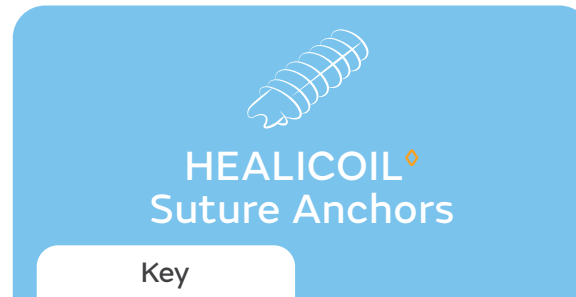
→ Not applicable (NA)

→ PT tears









→ Pre-clinical

Table of contents

→ **Click on the arrow** by the study reference to view the study overview.



Key

Author	Key finding				
Key evidence					
Chahla J, et al. 2020¹⁴	Significantly greater bone density surrounding HEALICOIL PK Suture Anchors versus TWINFIX [◇] PK Suture Anchors 6 months after rotator cuff repair				
Clark TR, et al. 2016¹⁵	Rotator cuff thickness significantly greater in patients who received vented compared with non-vented suture anchors at 6 weeks				
Yamauchi S, et al. 2021¹⁶	HEALICOIL Suture Anchors resulted in the high load-to-failure when compared with a series of different suture anchors used in rotator cuff repair				

Key to icons



Imaging outcomes



Patient outcomes



Biopsy



Biomechanical

 FT tears

 FT+PT tears

 Not applicable (NA)





 PT tears

 Pre-clinical

Table of contents

→ Click on the **arrow** by the study reference to view the study overview.



Author	Key finding				
Supporting evidence					
Kim J-H, et al. 2020¹⁷	Significantly improved bone ingrowth with HEALICOIL PK Suture Anchors versus TWINFIX [◊] HA Suture Anchors 6 months after rotator cuff repair	✓	✓		
Sano H, et al. 2016¹⁸	Fixation properties, stress distribution and failure patterns differed between coil-type and screw-type suture anchors for rotator cuff repair				✓

Key to icons



Imaging outcomes



Patient outcomes



Biopsy



Biomechanical

→ FT tears

→ FT+PT tears

→ Not applicable (NA)

→ PT tears

→ Pre-clinical

Table of contents

REGENESORB[®]
Material

Key

→ **Click on the arrow** by the study reference to view the study overview.

Author	Key finding				
Key evidence					
Sugaya H, et al. 2019¹⁹	REGENESORB Suture Anchors exhibited osteoconductivity at 2 years post-arthroscopic shoulder labral repair				
Vonhoegen J, et al. 2019²⁰	HEALICOIL REGENESORB Suture Anchor mostly resorbed and replaced by new bone material within 21 months of arthroscopic rotator cuff repair				

Key to icons



Imaging outcomes



Patient outcomes



Biopsy



Biomechanical

FT tears

FT+PT tears

Not applicable (NA)

PT tears

Pre-clinical

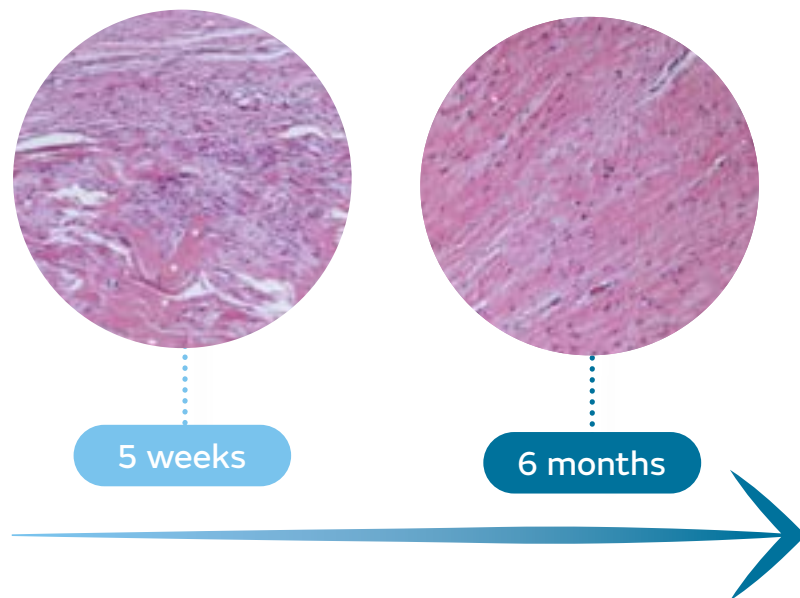


Product summary:

REGENETEN[®] Bioinductive Implant

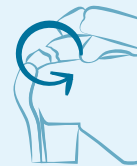The REGENETEN Implant has a large and growing evidence base in rotator cuff repair.^{1,2,4-6,8,9,11,13,21-23} By promoting the formation of new tendon-like tissue,^{1,2,8,23,24} the REGENETEN Implant changes the course of rotator cuff tear progression.^{2,3,12,23}

The REGENETEN Implant is resorbed and replaced by tendon-like tissue over 6 months^{1,24*}

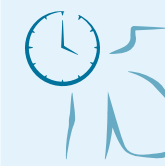

*On human biopsy (n=1) and in vivo sampling.

With a substantial body of literature evaluating its use in rotator cuff repair (>10 published clinical studies and >650 patients^{1,2,4-6,8,9,11,13,21-23†}), the REGENETEN Implant has been associated with:



Lower re-tear rates for FT tears versus standard repair techniques^{6,8,9,21}



Rapid post-operative recovery^{12,13,25}



Significant and clinically meaningful post-operative improvements in clinical outcomes^{4,7,13}




Low complication rates^{2,4,6-9,11,13,21,22}

†As of September 2022.

Effective treatment of rotator cuff tears can be challenging. Conventional treatment of PT tears commonly involves removing healthy tissue²⁶ and results in lengthy rehabilitation,²⁷ whilst repair of large FT tears has been associated with re-tear rates >50%.²⁵



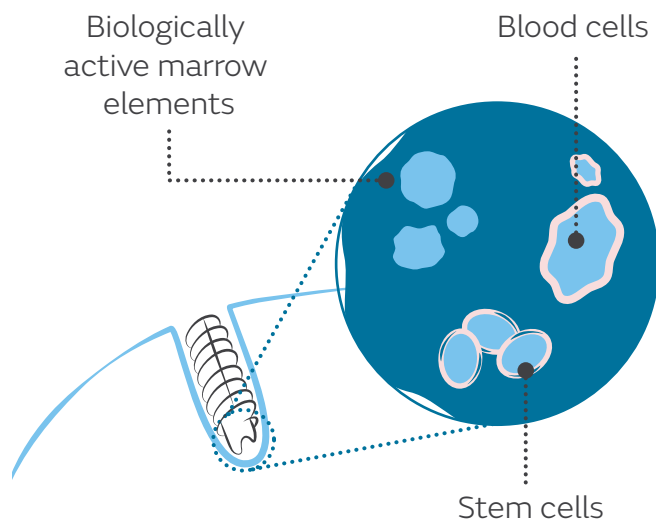


Product summary:

HEALICOIL[®] Suture Anchors

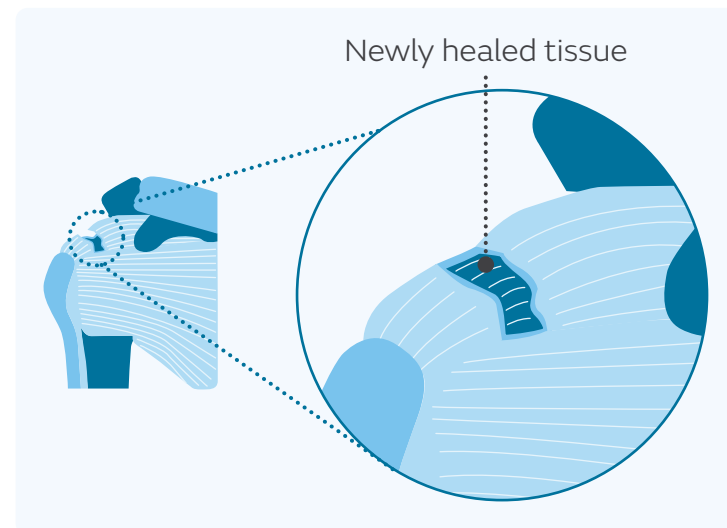
The unique open-architecture design of HEALICOIL Anchors, with threads extending in an open helical form along the anchor, allow access of blood, bone marrow and stem cells to the rotator cuff repair site.^{14,15} In clinical studies, HEALICOIL Anchors have been shown to aid tendon and bone healing: both increasing tendon thickness and the bone density surrounding the anchor compared with closed anchors.^{14,15}

Open-architecture design allows access of blood, bone marrow and stem cells to the repair site^{14,15}



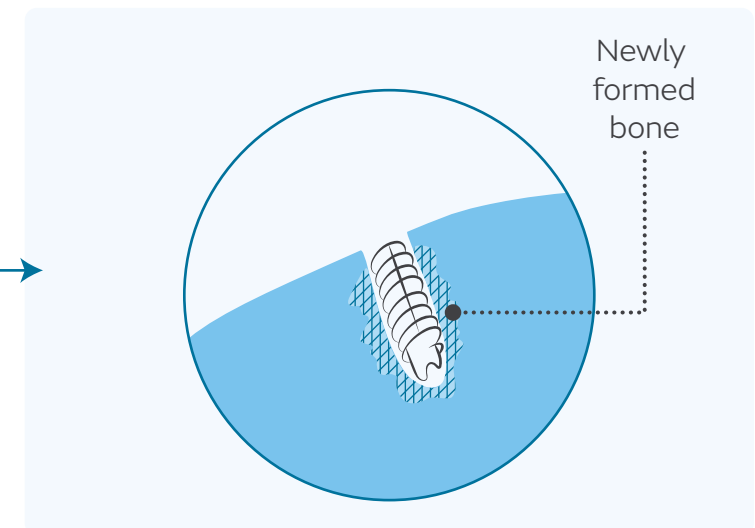
HEALICOIL Anchors have been found to support tendon and bone healing:

6 weeks



Significantly increased tendon thickness compared with closed anchors ($p=0.0074$)¹⁴


6 months



Significantly greater bone density surrounding the anchor compared with closed anchors ($p<0.05$)¹⁵

Suture anchor technology is continually evolving, with the ultimate goal being fixation that withstands rehabilitation, allows for increased healing and decreases failure.¹⁵





Product summary:

REGENESORB[®] Material

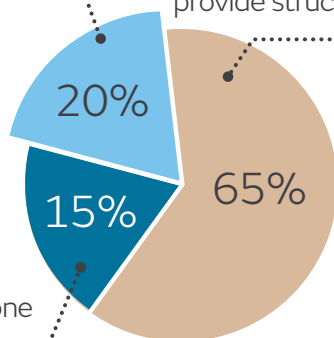
REGENESORB Material is composed of a unique formulation of proven materials designed to stimulate bone healing and formation.²⁸⁻³⁴ The material is absorbed and replaced by bone within 24 months,^{20,35,36} provides sustained mechanical stability^{20,35,36} and is not associated with severe osteolysis.²⁰

REGENESORB Material: a unique composition of proven materials²⁸⁻³⁴

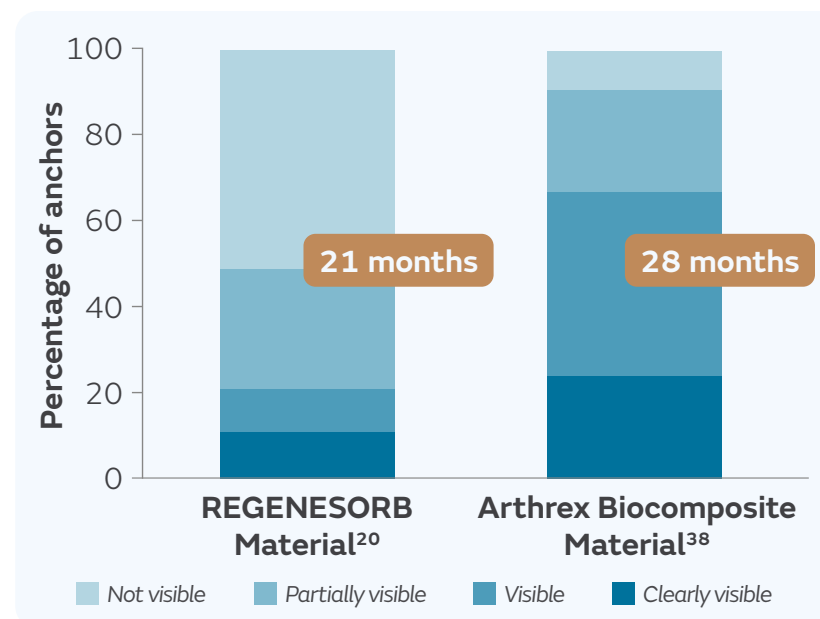
Calcium sulfate:
Works in early healing stages at 4-12 weeks^{30,31,34}

Poly L-lactic-co-glycolic acid (PLGA):
Comprised of natural products—lactic acid and glycolic acid^{29,33}—to provide structural integrity

β-tricalcium phosphate (β-TCP):
Sustained bone formation for over 18 months^{28,32}



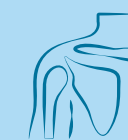Resorbed and replaced by bone faster than other biocomposite materials^{20,37,38}



With a history of established clinical use, REGENESORB Material is associated with:



Sustained mechanical stability^{20,35,36}



Resorption and replacement by bone within 24 months^{20,35,36}



No severe osteolysis²⁰

Important features of suture anchors that facilitate their successful use in rotator cuff repair include strong primary stability, short and complication-free resorption characteristics and new bone formation capability.^{20,38,39}





Histologic evaluation of biopsy specimens obtained after rotator cuff repair augmented with a highly porous collagen implant¹

Arnoczky SP, Bishai SK, Schofield B, et al. *Arthroscopy*. 2017;33:278–283.

Overview

Retrospective study to histologically evaluate host-tissue ingrowth, host-tissue maturation and host-implant biocompatibility in biopsies collected from 7 patients (FT tears, n=6; PT tears, n=1) between 5 weeks and 6 months after rotator cuff repair augmented with the REGENETEN[®] Bioinductive Implant

Results

- Rapid host cell ingrowth and early collagen formation at 5 weeks
- Compared with week 5 samples, increased collagen formation, maturation and organisation on the surface of the implant at 3 months (Figure 1)
- Implant no longer visible at 6 months, with new tendon-like tissue and highly oriented collagen indicative of functional loading (Figure 2)

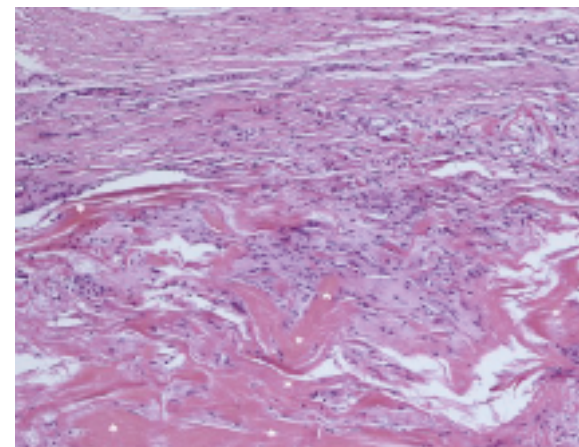


Figure 1. Photomicrograph of implant surface at 3 months. Remnants of implant still present () (haematoxylin and eosin x 100)

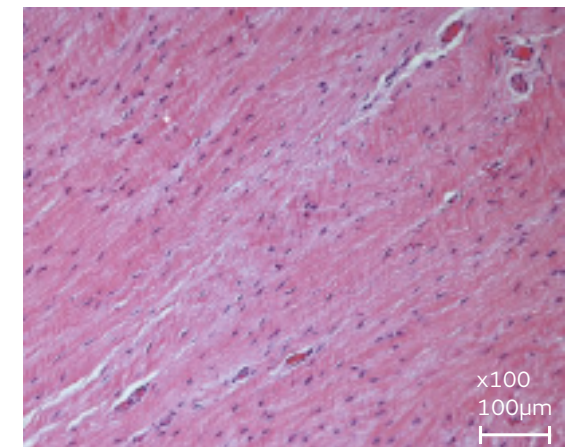


Figure 2. Photomicrograph of implant surface at 6 months. No evidence of implant remaining (haematoxylin and eosin x 100)

Images included with permission from Dr Craig L. Van Kampen

Conclusion

In a series of second-look biopsies, the REGENETEN Implant demonstrated rapid host cell ingrowth and collagen formation, leading to progressive maturation and functional loading of new tissue.



Evidence of healing of partial-thickness rotator cuff tears following arthroscopic augmentation with a collagen implant: a 2-year MRI follow-up²

Bokor DJ, Sonnabend D, Deady L, et al. *Muscles Ligaments Tendons J.* 2016;6:16–25.

Overview

Prospective study to evaluate new tissue formation, tear progression, pain and function in 13 patients with PT tears who received the REGENETEN[®] Bioinductive Implant after subacromial decompression without repair

Results

- Significant increase in mean tendon thickness, versus pre-operative values, at 3 and 24 months (both $p < 0.0001$)
- At 12 months, new tissue was indistinguishable from underlying tendon in 92% of patients (12/13)
- At both 12 and 24 months, all patients with measurable pre-operative tear sizes showed a reduction in tear size of ≥ 1 grade (n=10; Figure), with complete tear healing in 70% (7/10) of these patients
- Significant improvements versus pre-operative scores observed in clinical outcomes throughout 24-month follow-up period (CMS; CMS-pain; ASES total score; ASES pain score ($p \leq 0.01$))

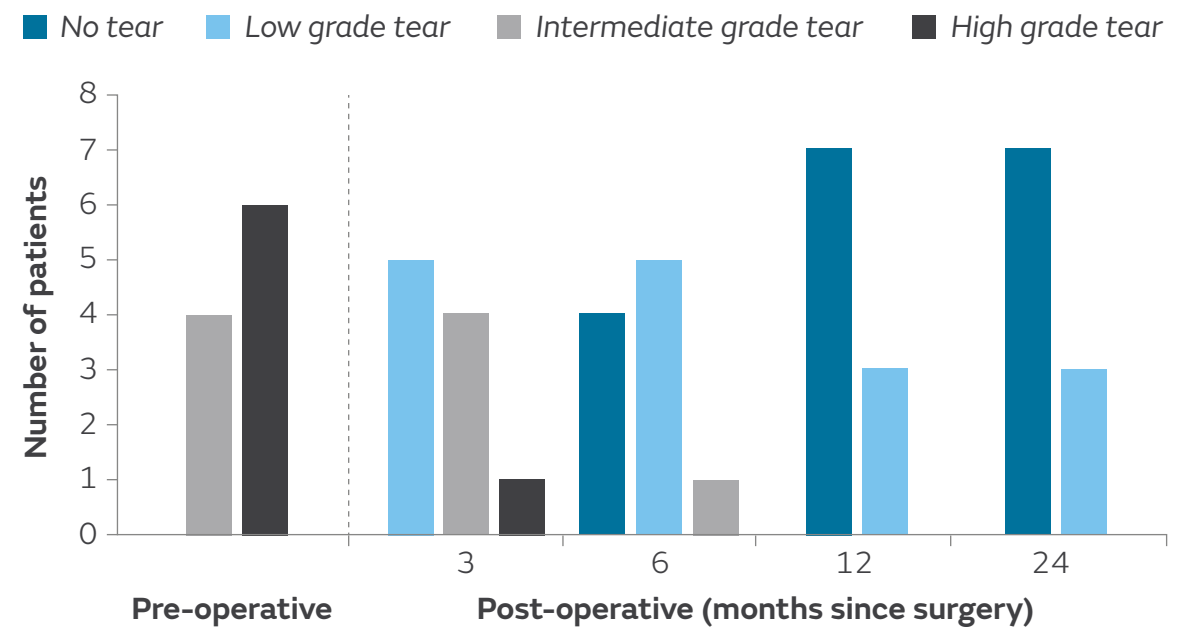


Figure. Sequential improvement and healing of rotator cuff defects over 24 months (n=10)

Conclusion

The REGENETEN Implant was associated with reductions in tear size and significant increases in mean tendon thickness at 3 and 24 months.



Healing of partial-thickness rotator cuff tears following arthroscopic augmentation with a highly-porous collagen implant: a 5-year clinical and MRI follow-up³

Bokor DJ, Sonnabend DH, Deady L, et al. *Muscles Ligaments Tendons J.* 2019;9:338–347.


Overview

5-year follow-up of a prospective, single-arm study, evaluating tendon integrity, tendon thickness, pain and function in patients with PT rotator cuff tears receiving the REGENETEN[®] Bioinductive Implant in lieu of standard repair. 11/13 enrolled patients were available for assessment at 5 years

Results

- 73% of patients (8/11) had no decline in tendon integrity between 2 and 5 years (Figure)
- Mean tendon thickness significantly decreased between 2 and 5 years (5.9 vs 5.2mm; $p=0.0012$), but remained significantly greater than pre-operative values (4.3mm; $p<0.0001$)
- Significant improvements from baseline in pain and function were sustained to 5 years ($p\leq 0.01$) and were not significantly different to 2-year values

11 patients available for 5-year follow-up



n=8

No decline in tendon integrity

n=2

New low grade tears at original site

n=1

New low grade tear distinct from original site

Figure. Change in tendon integrity (MRI) between 2- and 5-year follow-up

Conclusion

Most patients treated with the REGENETEN Implant had no decline in tendon integrity between 2 and 5 years, with sustained improvements in patient-reported outcomes at 5 years.



Treatment of partial-thickness rotator cuff tears with a resorbable bioinductive bovine collagen implant: 1-year results from a prospective multicenter registry⁴

Bushnell BD, Bishai SK, Krupp RJ, et al. *Orthop J Sports Med.* 2021;9:23259671211027850.

Overview

Prospective, multicentre registry analysis evaluating patient-reported outcomes in 272 patients with PT tears (REGENETEN[®] Bioinductive Implant alone, n=241; or REGENETEN Implant with takedown and repair for patients with grade 2 or 3 tears, n=31)

Results

- Mean PROM scores were significantly improved at 3, 6 and 12 months post-operatively versus pre-operative values (all $p < 0.02$), except for VR-12 MCS, which was only significantly improved at 12 months ($p = 0.016$; Table)
 - MCIDs for ASES, SANE, and WORC scores were met or exceeded by >90% of patients at 12 months
- Compared with the augmented takedown and repair group, use of the REGENETEN Implant alone in higher grade tears (grade ≥ 2) resulted in:
 - Significantly better ASES, SANE and WORC scores at 2 and 6 weeks ($p < 0.05$ for all comparisons)
 - No significant differences in 12-month mean PROM scores, except for VR-12 PCS, which was significantly improved with use of the REGENETEN Implant alone ($p = 0.0213$)

	Pre-operative	3 months	12 months
ASES pain	5.5±2.4	2.1±2.4 [†]	1.1±2.0 [†]
ASES function	14.1±6.2	18.9±6.9 [†]	26.1±5.9 [†]
ASES overall	46.8±18.2	71.9±20.5 [†]	88.1±17.9 [†]
SANE	41.7±19.9	69.9±19.4 [†]	86.2±18.2 [†]
VR-12 MCS	51.9±13.2	54.6±12.0	55.4±8.9 [†]
VR-12 PCS	35.3±8.4	43.1±8.3 [†]	49.2±9.3 [†]
WORC	36.4±16.6	64.0±22.6 [†]	83.7±21.7 [†]

Table. Mean±SD PROM scores before and after treatment of PT rotator cuff tears with the REGENETEN Implant*

*Overall population (n=227), including the REGENETEN Implant alone and augmented takedown and repair groups. [†] $p < 0.02$ vs pre-operative values

Conclusion

The REGENETEN Implant, used alone or with takedown and repair, significantly improved pain, shoulder function and HRQoL at 3, 6 and 12 months. Use of the REGENETEN Implant in lieu of standard repair offered improved early clinical outcomes and comparable 12-month outcomes to takedown and repair.



Bioinductive collagen implants facilitate tendon regeneration in rotator cuff tears⁵

Camacho-Chacon JA, Cuenca-Espierrez J, Roda-Rojo V, et al. *J Exp Orthop*. 2022;9:53.

Overview

Prospective study to evaluate tendon integrity, histological characteristics of tendon biopsy samples, pain and function in 30 consecutive patients with rotator cuff tears who received the REGENETEN[®] Bioinductive Implant alone for patients with PT tears (n=18) and double-row transosseous-equivalent repair augmented with REGENETEN Implant for FT tears (n=12)

Results

- Biopsies of repair tissue obtained at 6 months showed an absence of inflammatory, scarring or ischaemic changes (Figure)
- New tendon-like tissue indistinguishable from native tendon on MRI was observed in all samples at 6 months, and remained unmodified at 12 months
- MRI evidence demonstrated complete healing in 27/30 patients after 6 months, with a >50% reduction in defect size versus pre-operative size in the other 3 cases
- Patients experienced statistically significant improvements versus pre-operative values in VAS pain (p=0.003), ASES score (p=0.001) and CMS (p=0.001) at 6 months post-operatively, which were sustained at 12 months

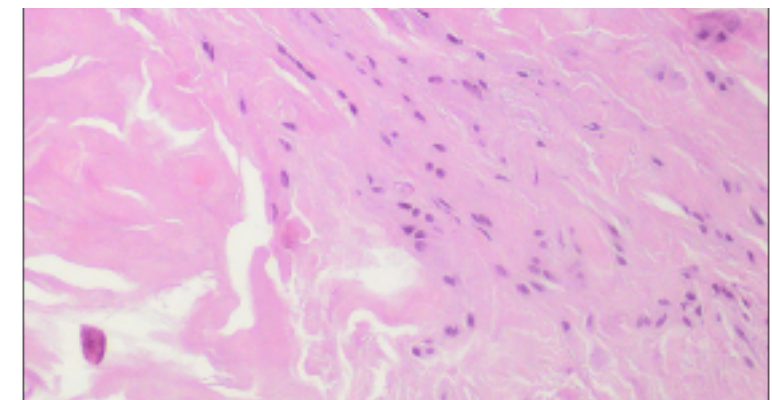


Figure. Light photomicrograph of newly regenerated host tissue at 6 months post-operatively

Figure adapted from Camacho-Chacon JA, et al. *J Exp Orthop*. 2022; 9:53. Article licensed under a Creative Commons Attribution 4.0 International License (<https://creativecommons.org/licenses/by/4.0>)

Conclusion

Rotator cuff repair with the REGENETEN Implant was shown to result in tendon-like tissue in all biopsy samples, which was indistinguishable from the native tendon, with complete healing achieved in 90% of patients at 6-months post-operatively.



Augmentation of a transosseous equivalent repair in posterosuperior non-acute rotator cuff tears with a bioinductive collagen implant decreases the re-tear rate at one year

Ruiz Ibán MA, Navlet MG, Marco SM, et al. *Arthroscopy*. 2023 Dec 28. [Epub ahead of print]

Overview

A blinded, multi-centre, randomised controlled trial comparing the healing rates of rotator cuff tears for patients with medium and large FT tears. Patients received either arthroscopic transosseous equivalent double-row rotator cuff repair alone (control group; n=62) or the same repair augmented with the REGENETEN[®] Bioinductive Implant (n=60)

Results

- At 12-months follow-up, compared with repair alone, patients receiving the REGENETEN Implant demonstrated:
 - Significantly lower re-tear rate (8.3 vs 25.8%; p=0.01; Figure)
 - Significantly better tendon integrity (91.7 vs 74.2%; p=0.03)
 - A three times lower risk of re-tear (RR=0.32; 95% CI: 0.13–0.83; Figure)
 - No differences in clinical outcome measures between groups
 - No difference in the number of serious or minor complications

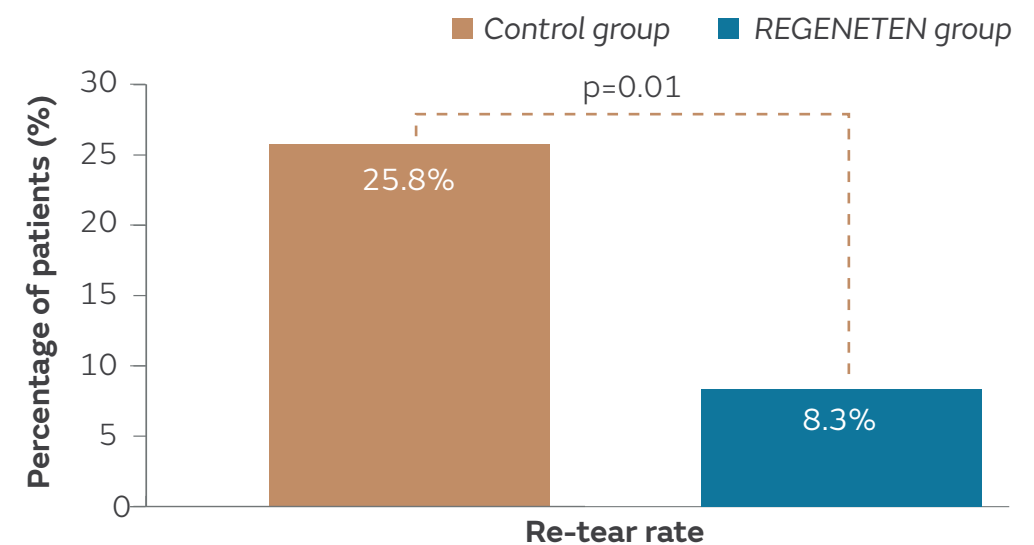


Figure. Percentage of patients with a re-tear assessed on MRI in the control and REGENETEN Implant groups at 12-months post-operatively

Conclusion

In a randomised controlled trial, results assessed on MRI at 12-months post-operatively demonstrated that repair of medium and large full-thickness tears augmented with the REGENETEN Bioinductive Implant led to better tendon integrity, reduced risk of re-tear and significantly lower re-tear rates compared with repair alone.



Isolated bioinductive repair of partial-thickness rotator cuff tears using a resorbable bovine collagen implant: two-year radiologic and clinical outcomes from a prospective multicenter study⁷

Schlegel TF, Abrams JS, Angelo RL, Getelman MH, Ho CP, Bushnell BD. *J Shoulder Elbow Surg.* 2021;30:1938–1948.

Overview

Prospective, multicentre case series evaluating tear size, tendon thickness, pain and function in 33 patients receiving REGENETEN[®] Bioinductive Implant in lieu of standard repair for intermediate- (n=12) or high-grade (n=21) PT tears

Results

- At 24 months, 87% of tears (26/30) reduced in size by >50% from pre-operative measurements (Figure)
- No progression to FT tears in patients compliant with the rehabilitation protocol (n=32)
- Improvements in CMS met or exceeded MCIDs in all patients with intermediate-grade tears and 94% of patients with high-grade tears
- No significant difference in pain, function or tendon healing were observed in different tear locations, including articular-sided (n=11), bursal-sided (n=10), intrasubstance (n=4) and hybrid (n=8) tears

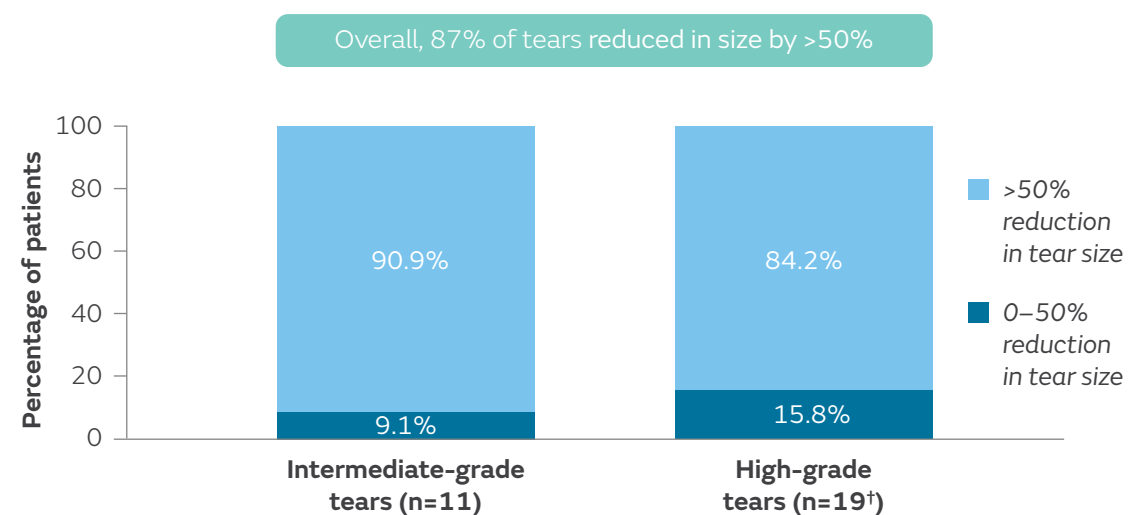


Figure. Degree of reduction in tear size from baseline to 24 months in patients receiving the REGENETEN Implant

[†]Tear size could not be determined for one patient with a high-grade tear

Conclusion

The REGENETEN Implant reduced 87% of PT tears in size by >50% at 24 months. Improvements in pain, function, tear healing and tendon thickness were consistent across all tear locations.



Evaluation of healing rates and safety with a bioinductive collagen patch for large and massive rotator cuff tears: 2-year safety and clinical outcomes⁸

Thon SG, O'Malley L 2nd, O'Brien MJ, Savoie FH 3rd. *Am J Sports Med.* 2019;47:1901–1908.

Overview

Prospective study evaluating tendon healing rates, failure rates, tendon thickness, ASES score and safety in 23 patients receiving a REGENETEN[®] Bioinductive Implant in conjunction with double-row repair of large (n=11) or massive (n=12) rotator cuff tears

Results

- No implant-related adverse events
- Tendon healing in 22/23 patients (96%) on ultrasound at 24 months
- Treatment success in 21/23 patients (91%) at 24 months, including 100% (7/7) success in primary repairs and 88% (14/16) in revision repairs (Figure); one additional clinical failure due to progression of glenohumeral osteoarthritis
- Mean tendon thickness on ultrasound increased from 6.29mm at 3 months to 7.72mm at 12 months, decreasing to 7.28mm at 24 months

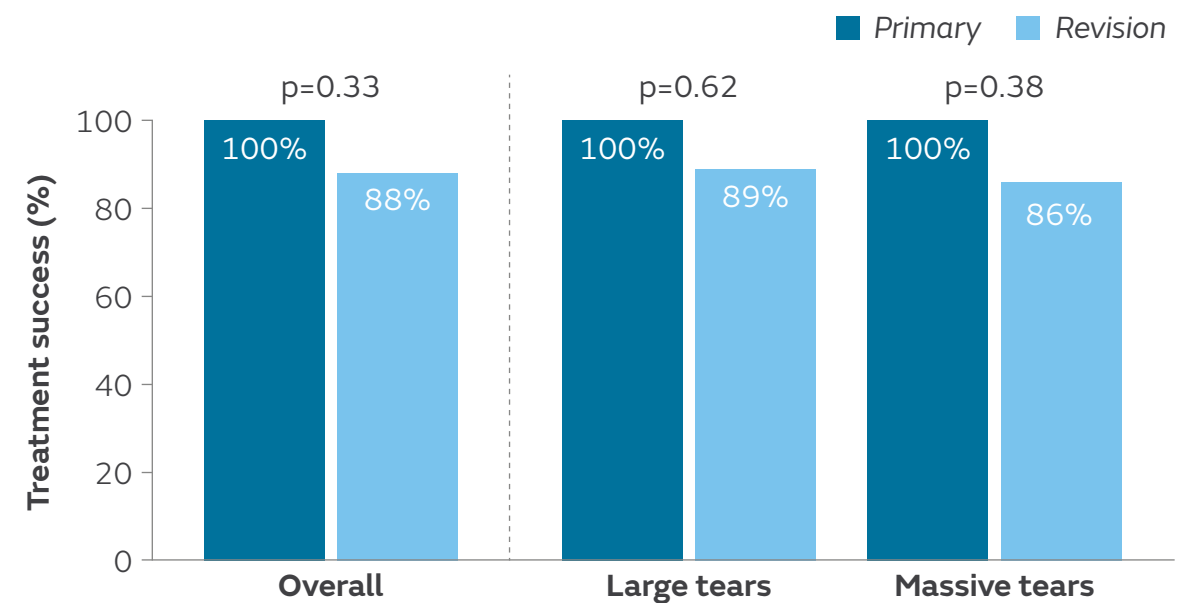


Figure. Percentage of patients achieving treatment success in primary and revision repairs

Conclusion

In conjunction with double-row repair of large and massive rotator cuff tears, the REGENETEN Implant was safe, induced tissue formation and led to a high tendon healing rate in both primary and revision settings.



Preliminary investigation of a biological augmentation of rotator cuff repairs using a collagen implant: a 2-year MRI follow-up⁹

Bokor DJ, Sonnabend D, Deady L, et al. *Muscles Ligaments Tendons J.* 2015;5:144–150.

Overview

Prospective study evaluating re-tear rates, tendon thickness, pain and function in 9 patients with supraspinatus tendon tears (8 medium-sized FT tears, 1 PT tear converted to a FT tear during surgery) who received the REGENETEN[®] Bioinductive Implant in conjunction with standard repair

Results

- No MRI evidence of re-tear or gap formation at 24 months
- Significantly greater mean tendon thickness on MRI in study patients versus published values from young, healthy adults with no previous shoulder problems, sustained to 24 months ($p < 0.01$; Figure)
- New tissue was indistinguishable from the native tendon on MRI at 12 months
- Significant improvements in ASES score and CMS from pre-operative values at 24 months (both $p < 0.001$)

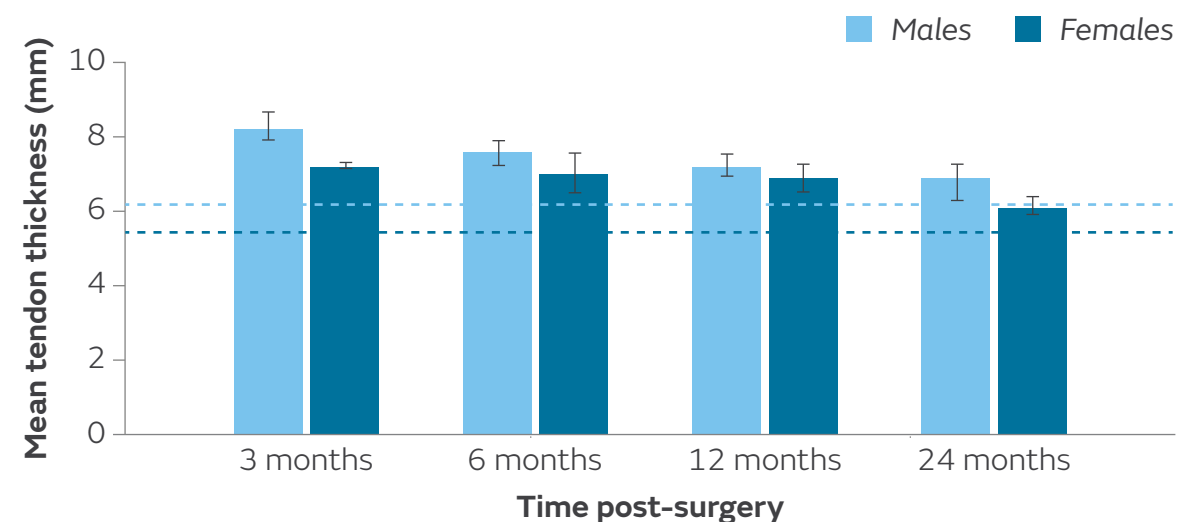


Figure. Mean \pm SEM tendon thickness in male ($n=6$) and female ($n=3$) patients compared to published average thicknesses (horizontal lines) for healthy males (---) and females (---); $p < 0.01$ at all time points

Conclusion

The REGENETEN Implant facilitates restoration of the normal tendon footprint and ultimately maintains repair integrity of FT tears at 24 months.



Two-year outcomes with a bioinductive collagen implant used in augmentation of arthroscopic repair of full-thickness rotator cuff tears: final results of a prospective multi-center study¹⁰

Bushnell BD, Connor P, Harris HW, Ho CP, Trenhaile SW, Abrams JS. *J Shoulder Elbow Surg.* 2022 Jul 1. [Epub ahead of print]

Overview

Prospective, multicentre study to evaluate re-tear rates, tendon thickness, implant resorption, pain and function in patients who received either single- or double-row repair of medium-sized (n=66) and large (n=49) FT rotator cuff tears augmented with REGENETEN[®] Bioinductive Implant

Results

- Overall re-tear rate of 4.6% at 3 months (3/66), 10.6% at 12 months and 24 months (7/66) in medium tears. Overall re-tear rate of 20.4% at 3 months (10/49), 24.5% at 12 months (12/49) and 28.6% at 24 months (14/49) in large tears
- Significantly lower re-tear rate in patients who had repair with double-row (13.2%; 12/91) technique than single-row (37.5%; 9/24) at 24 months (p=0.0061)
- More than 90% of patients with medium and large tears had post-operative improvements in ASES Shoulder score and CMS at 24 months that exceeded MCIDs (p<0.001; Figure)
- 97.1% of patients were satisfied with the procedure; 100% would recommend the procedure to a friend

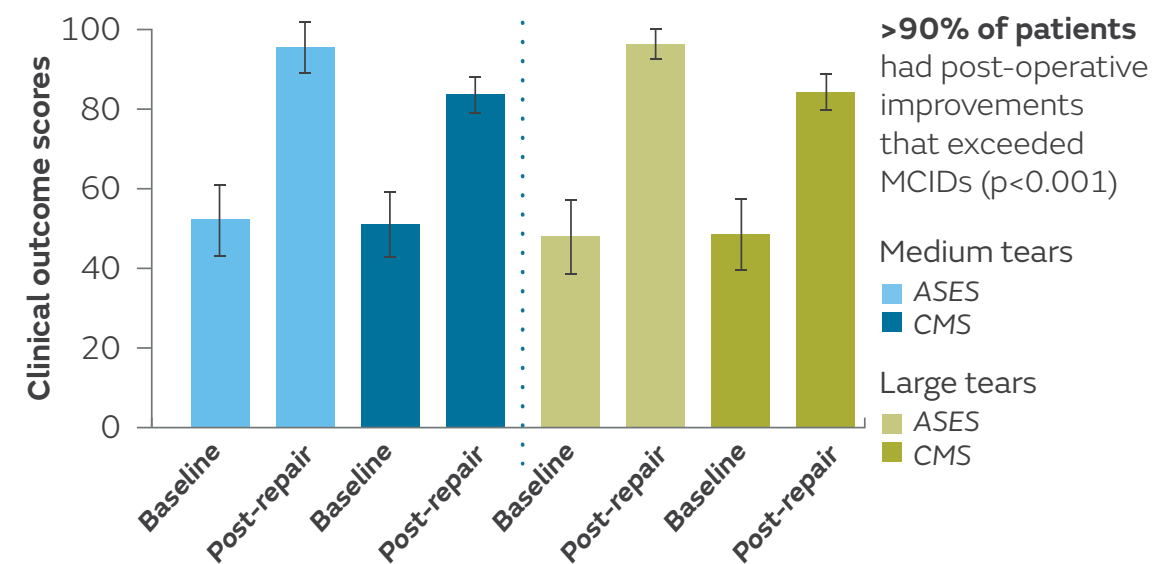


Figure. Patients baseline ASES score and CMS for medium and large tears versus post-repair at 24 months

Conclusion

In combination with repair, the REGENETEN Implant led to low 2-year re-tear rates, improvements in pain and function and high patient satisfaction. The authors note that this study reports lower re-tear rates than studies evaluating standard repairs.



Collagen-based bioinductive implant for treatment of partial thickness rotator cuff tears¹¹

Dai A, Campbell A, Bloom D, Baron S, Begly J, Meislin R. *Bull Hosp Jt Dis.* 2020;78:195–201.

Overview

Retrospective case series evaluating pain, function, patient satisfaction, tendon thickness and implant-related complications in 24 patients who received the REGENETEN[®] Bioinductive Implant in lieu of standard repair

Results

- Significant increase in mean ASES score ($p=0.001$) and significant decrease in mean VAS pain ($p<0.001$) at 19.1 months post-operation compared to pre-operative values
 - Improvements in ASES score (Figure) and VAS pain were greatest in articular-sided ($n=16$) and intrasubstance tears ($n=3$)
- Mean patient satisfaction score was 7.5/10 at 19.1 months post-operation
- Mean tendon thickness significantly increased from 5.7mm pre-operation to 6.5mm at 9.9 months post-operation ($p=0.007$)
- No implant-related complications; one patient had a traumatic re-tear 4 months post-operatively

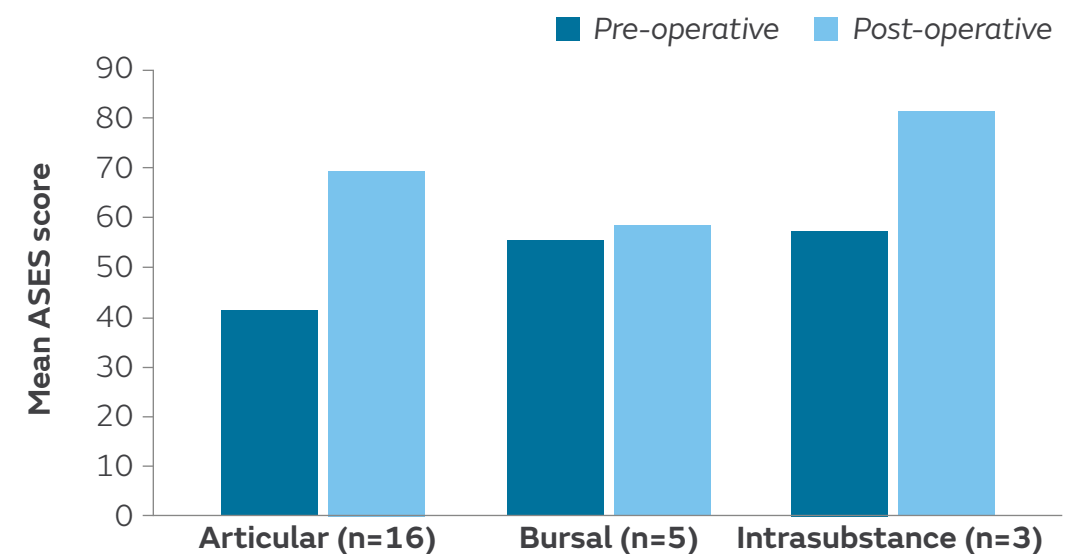


Figure. Mean ASES score before and at a mean 19.1 months after repair with the REGENETEN Implant

Conclusion

The REGENETEN Implant in lieu of standard repair significantly improved post-operative pain and function scores in patients with PT rotator cuff tears, with greatest improvements in articular-sided and intrasubstance tears.



Patient-reported outcomes after use of a bioabsorbable collagen implant to treat partial and full-thickness rotator cuff tears¹²

McIntyre LF, Bishai SK, Brown PB 3rd, Bushnell BD, Trenhaile SW. *Arthroscopy*. 2019;35:2262–2271.

Overview

Multicentre registry study evaluating post-operative recovery and patient-reported outcome measures of pain and function in 173 patients who received a REGENETEN[®] Bioinductive Implant in lieu of standard PT repair (n=90) or in conjunction with standard repair of FT tears (n=83)

Results

- In PT tears, mean improvements exceeded MCIDs in VAS pain from 2 weeks and ASES score from 6 weeks post-operatively (both $p < 0.001$)
- In FT tears, mean improvements exceeded MCIDs in VAS pain from 2 weeks and ASES score from 3 months post-operatively (both $p < 0.001$)
- SANE score, WORC and VR-12 PCS also improved significantly from baseline during the study period in both tear types (all $p < 0.001$)
- Post-operative recovery was rapid in PT tears (Table)

Measure	REGENETEN Implant	
	No biceps surgery	Concomitant tenodesis
Time in sling	10.6 days	27.7 days
Return to driving	14.6 days	
Return to work	9.4 days Sedentary work	72.9 days Physical work
Return to athletics	65.6 days Overall	117.9 days Overhead athletics
Duration of opioid use	18.3 days	

Table. Duration of post-operative recovery in patients with PT tears

Conclusion

The REGENETEN Implant led to clinically meaningful improvements in pain and function for patients with PT and FT tears, with rapid post-operative recovery in PT tears.



Full-thickness rotator cuff tears can be safely treated with a resorbable bioinductive bovine collagen implant: one-year results of a prospective, multicenter registry¹³

McIntyre LF, McMillan S, Trenhaile SW, Bishai SK, Bushnell BD. *Arthrosc Sports Med Rehabil.* 2021;3:e1473–e1479.

Overview

Prospective, multicentre registry study to evaluate pain, function and post-operative recovery in 210 patients who had FT tears repaired and augmented with the REGENETEN[®] Bioinductive Implant

Results

- ASES, SANE, VR-12 PCS and WORC scores significantly improved from pre-operative values at 6 and 12 months ($p < 0.001$; Figure)
 - At 12 months, MCIDs were met or exceeded by 90.5% (86/95) of patients for ASES, 84.3% (161/191) for SANE and 87.2% (116/133) for WORC
 - Mean PROM scores for all measures were consistent at 12 months across different pre-operative tear sizes (small and medium versus large and massive tears)
- Revision rate of 9.4% (18/192 patients, 22 procedures in total); re-tear ($n=11$), infection ($n=3$), shoulder stiffness/adhesive capsulitis ($n=3$), bursitis ($n=1$) or implant displacement after a fall ($n=1$)^{*}

^{*}Revisions could be attributed to multiple reasons.

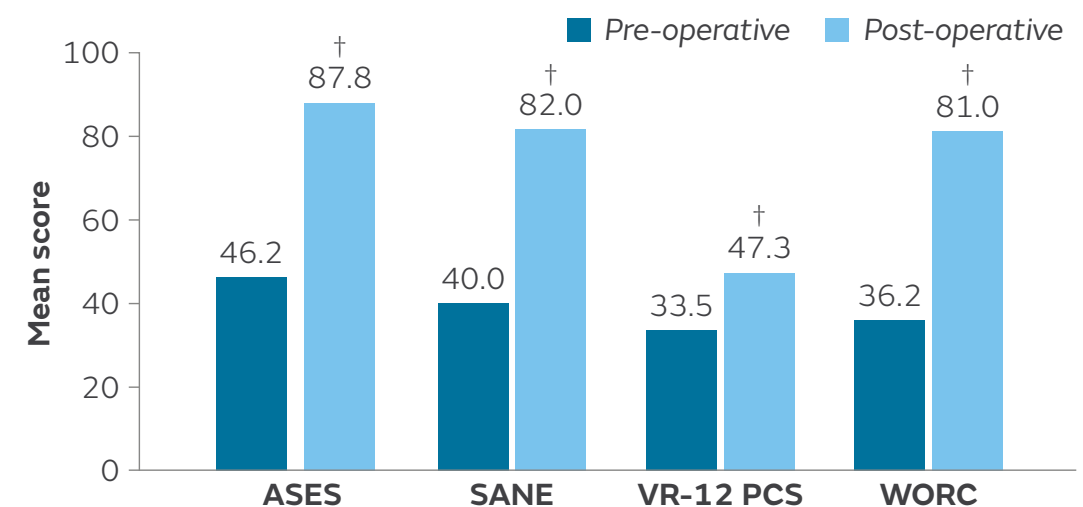


Figure. Mean PROM scores before and 12 months after repair of FT tears augmented with the REGENETEN Implant

VR-12 PCS: standardised measure, higher scores reflect better HRQoL (physical aspects only)

[†] $p < 0.001$ vs pre-operative value

Conclusion

Use of the REGENETEN Implant led to significant improvements in pain, shoulder function and HRQoL in patients with FT tears at 12 months compared to pre-operative values, regardless of pre-operative tear size.



Bony ingrowth of coil-type open-architecture anchors compared with screw-type PEEK anchors for the medial row in rotator cuff repair: a randomized controlled trial¹⁴

Chahla J, Liu JN, Manderle B, et al. *Arthroscopy*. 2020;36:952–961.

Overview

Single-centre randomised controlled trial evaluating bone density, bone mass, pain and shoulder function after double-row repair of FT rotator cuff tears, with the medial row fixated with either open architecture HEALICOIL[◇] PK Anchors (n=21) or screw-type TWINFIX[◇] PK Anchors (n=19)

Results

- HEALICOIL PK Anchors had significantly greater bone density at, and up to, 1.50mm from the anchor surface compared to TWINFIX PK Anchors at 6 months (p<0.05; Figure)
- HEALICOIL PK Anchors had significantly more total bone mass within the anchor site compared to TWINFIX PK Anchors at 6 months (p<0.01); there was no significant difference in density
- Pain and shoulder function improved significantly from baseline to 12 months in both groups (p<0.05)

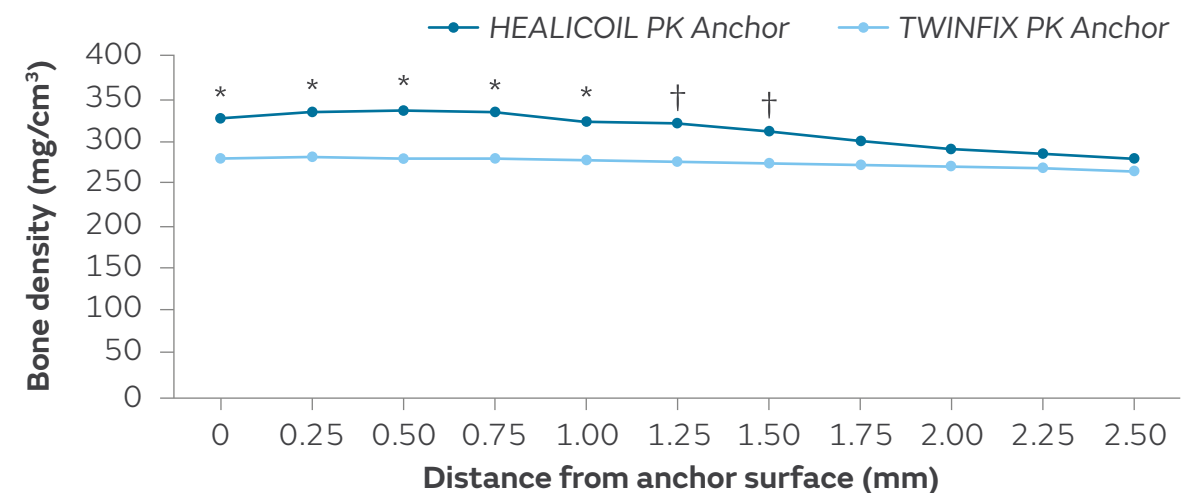


Figure. Bone density by distance from anchor surface with HEALICOIL PK Anchors (n=21) and TWINFIX PK Anchors (n=19) on 6-month CT scans

*p<0.01, †p<0.05

Conclusion

Open architecture HEALICOIL PK Anchors had significantly greater bone density surrounding the anchor compared to screw-type TWINFIX PK Anchors 6 months after rotator cuff repair. The authors suggested that increased bone density around the anchor may contribute to a stronger construct during post-operative rehabilitation.



Do vented suture anchors make a difference in rotator cuff healing¹⁵

Clark TR, Guerrero EM, Song A, O'Brien MJ, Savoie FH. *Ann Sports Med Res.* 2016;3:1068.

Overview

Retrospective study comparing tendon thickness following primary rotator cuff repair in patients who received either open architecture (HEALICOIL[◇] REGENESORB[◇] Suture Anchor; n=40) or non-vented suture anchors (Healix Advance[™] Anchor*; n=30)

Results

- Mean rotator cuff thickness was significantly greater in patients who received HEALICOIL REGENESORB Anchors versus Healix Advance Anchors, on 6-week ultrasound (p=0.0074; Figure)
- In addition to anchor type, mean post-operative rotator cuff thickness was also significantly related to gender (p=0.022), age (p<0.001) and days since surgery (p=0.004)

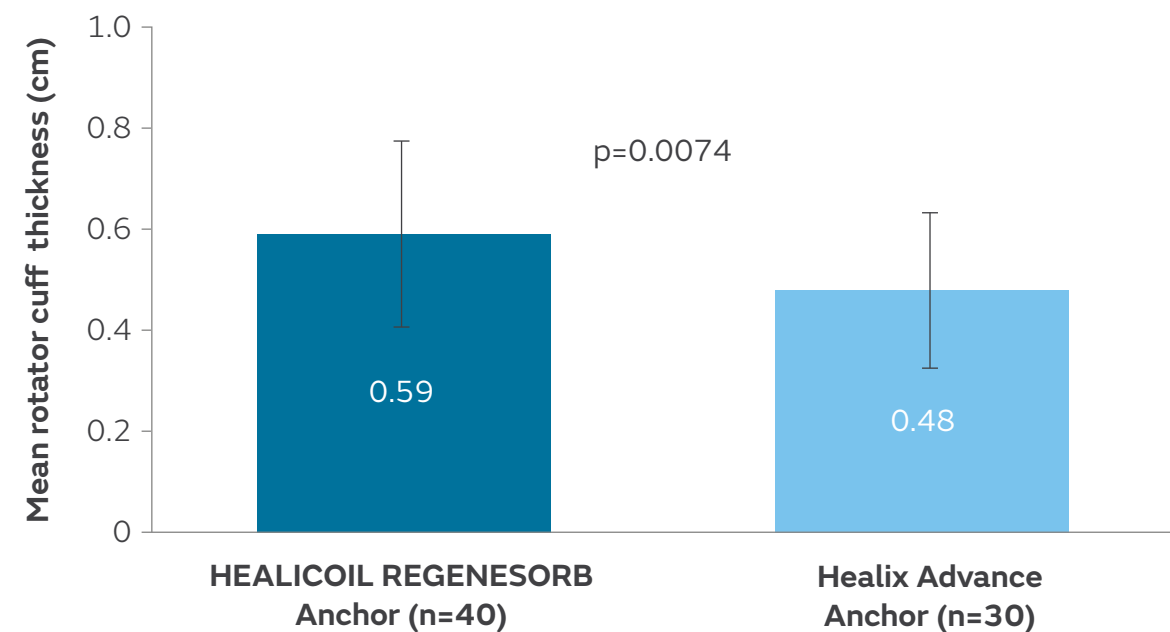



Figure. Mean±SD rotator cuff thickness at 6 weeks post-operatively

*Manufactured by DePuy Synthes, Raynham, MA, USA.

Conclusion

Patients treated with vented HEALICOIL REGENESORB Anchors had a significantly greater rotator cuff thickness at 6 weeks versus those treated with non-vented anchors.



Biomechanical analysis of bioabsorbable suture anchors for rotator cuff repair using osteoporotic and normal bone models¹⁶

Yamauchi S, Tsukada H, Sasaki E, et al. *J Orthop Sci.* 2022;27:115–121.

Overview

Biomechanical study comparing the load-to-failure of 16 different suture anchors (varying by material composition, diameter and design) used in rotator cuff repair, using normal and osteoporotic bone models

Results

- Among the 4.5–4.75mm anchors, HEALICOIL[◇] REGENESORB[◇] 4.75mm showed the highest load-to-failure in the normal model ($237.9 \pm 3.5\text{N}$; Figure) and the osteoporotic model ($119.0 \pm 1.4\text{N}$)
- Among the 5.5mm anchors, HEALICOIL REGENESORB showed the highest load-to-failure ($266.1 \pm 7.9\text{N}$) in the normal model and HEALICOIL PK showed the highest load-to-failure ($146.3 \pm 5.8\text{N}$) in the osteoporotic model
- In the normal bone model, TWINFIX[◇] Ti 6.5mm showed the highest mean \pm SD load-to-failure ($304.0 \pm 15.2\text{N}$)

*Manufactured by Arthrex, Naples, FL, USA.

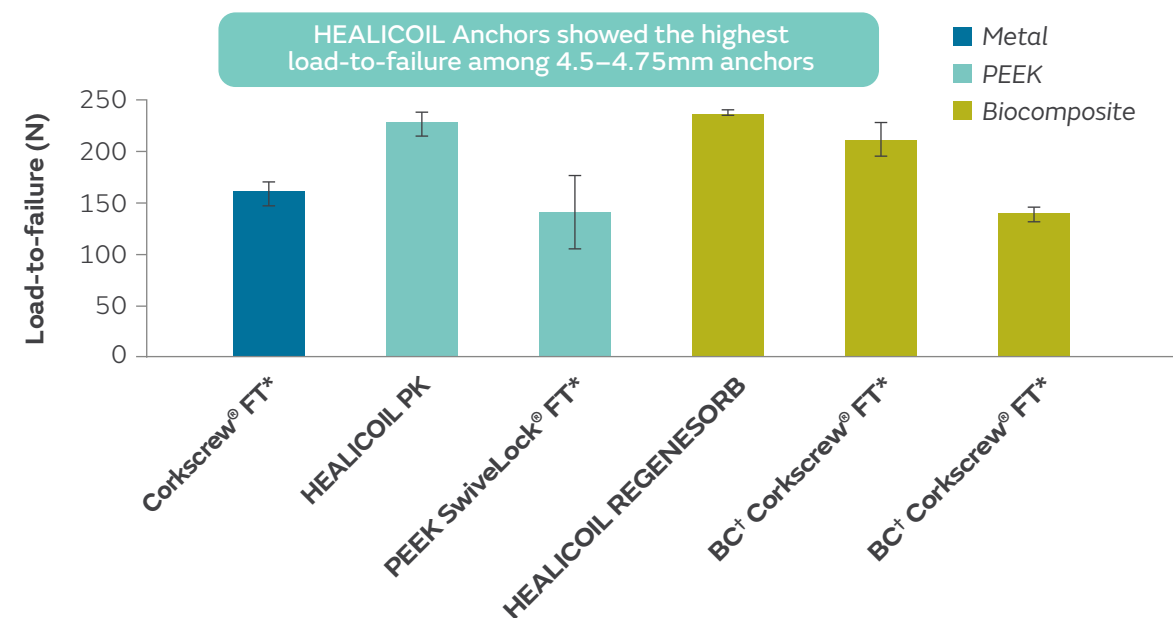


Figure. Comparison of load-to-failure in normal bone model among 4.5–4.75mm anchors
†Biocomposite

Conclusion

HEALICOIL Anchors showed the highest load-to-failure out of all anchors, except for TWINFIX Ti 6.5mm in the normal bone model.



A comparison of open-construct PEEK suture anchor and non-vented biocomposite suture anchor in arthroscopic rotator cuff repair: a prospective randomized clinical trial¹⁷

Kim JH, Kim YS, Park I, et al. *Arthroscopy*. 2020;36:389–396.

Overview

Randomised controlled trial in two South Korean hospitals evaluating bone ingrowth, cyst formation, re-tear rates, pain and shoulder function 6 months after rotator cuff repair with open-architecture HEALICOIL[◇] PK Anchors (n=36) or non-vented TWINFIX[◇] HA Anchors (n=33)

Results

- Significantly more HEALICOIL PK Anchors demonstrated good or excellent bone ingrowth compared to TWINFIX HA Anchors (69.5 vs 36.3%; $p < 0.001$; Figure)
- No significant differences between HEALICOIL PK Anchor and TWINFIX HA Anchor groups in rates of cyst formation (14 vs 12%) and re-tear (5 vs 5%)
- Significant improvements in shoulder function and pain relief from baseline with both anchors ($p < 0.001$); no significant differences between groups

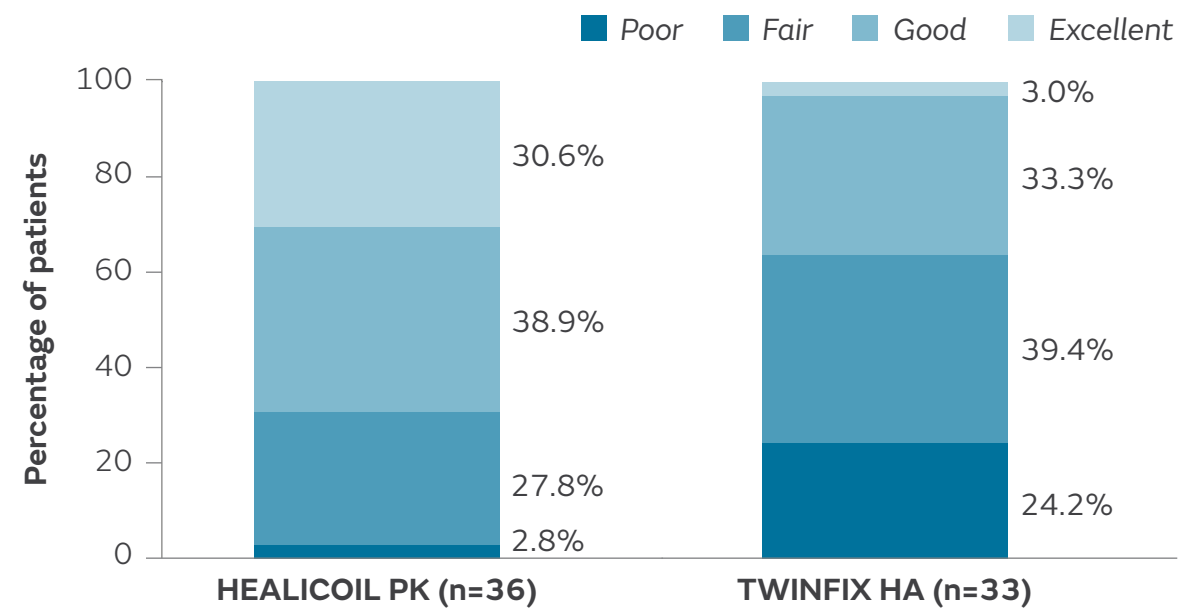


Figure. Bone ingrowth (modified Barber's ossification scale) with HEALICOIL PK Anchors and TWINFIX HA Anchors on 6-month CT scans

Conclusion

Open-architecture HEALICOIL PK Anchors significantly improved bone ingrowth compared to non-vented TWINFIX HA Anchors 6 months after rotator cuff repair.



Comparison of fixation properties between coil-type and screw-type anchors for rotator cuff repair: a virtual pullout testing using 3-dimensional finite element method¹⁸

Sano H, Tokunaga M, Noguchi M, et al. *J Orthop Sci.* 2016;21:452–457.

Overview

Biomechanical study using 3D-FEM virtual pull-out testing to compare fixation properties, stress distribution and failure patterns in screw-type (TWINFIX[◇] Ti Suture Anchor) and open architecture (HEALICOIL[◇] PK Suture Anchor and HEALICOIL REGENESORB[◇] Suture Anchor) suture anchors. Computer models of each anchor were inserted into a model of cancellous bone prior to simulation of a traction force

Results

- Site of highest stress distribution and element failure differed by anchor type:
 - Around the proximal threads of the screw-type TWINFIX Ti Anchor
 - Near the distal tip and site of suture thread attachment in both coil-type HEALICOIL Anchors
- HEALICOIL REGENESORB Anchors showed the least displacement of the three anchors (Figure)

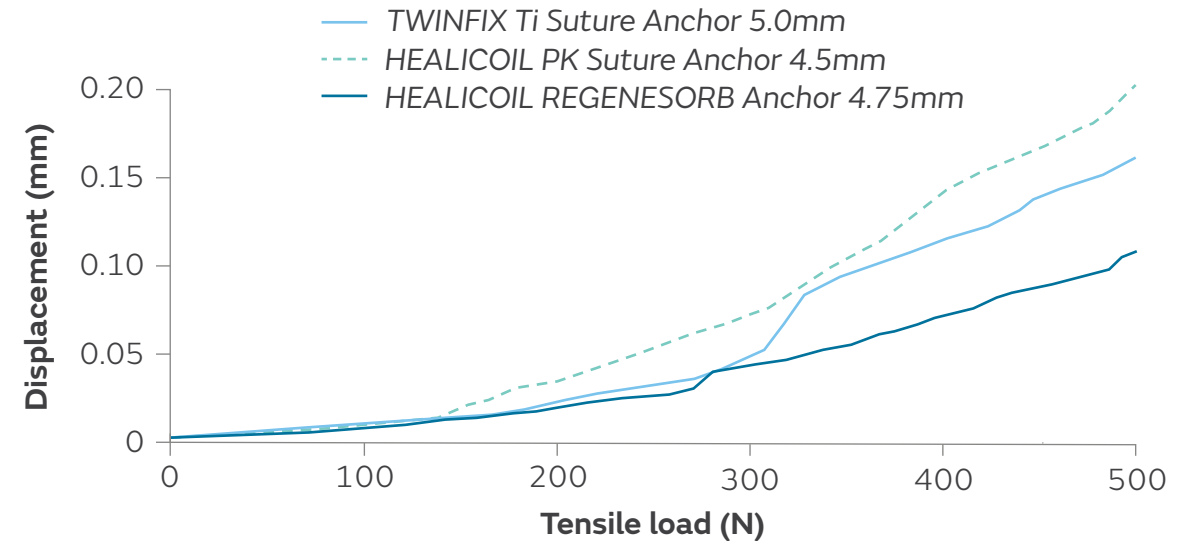



Figure. Mean value of displacement for open architecture and screw-type suture anchors

Conclusion

Failure of the screw-type TWINFIX Ti Anchor occurred closer to the bone surface than with the open architecture HEALICOIL Anchors in virtual pull-out testing. As proximal bony tissue is often damaged during repair, this may indicate a greater risk of pull-out with screw-type anchors.



Osteointegration of a biocomposite suture anchor after arthroscopic shoulder labral repair¹⁹

Sugaya H, Suzuki K, Yoshimura H, et al. *Arthroscopy*. 2019;35:3173–3178.

Overview

Clinical trial evaluating osteoconductivity, tissue density of anchor sites, shoulder function and adverse events at 2 years post-arthroscopic labral repair with 148 REGENESORB[®] Anchors* implanted in 37 shoulders with traumatic instability (n=37 patients)

Results

- Ossification was observed in 89.9% (133/148) of anchor sites, with no significant difference between 2.3mm and 2.9mm anchors, or between anchor sites (Figure)
- Mean tissue density of anchor sites was significantly greater than infraspinatus muscle ($p < 0.001$) but significantly lower than cancellous bone ($p < 0.001$)
- Significant improvements in shoulder function scores were observed at 2 years post-operatively compared to pre-operative levels:
 - JSS-SIS: 96.3 ± 4.7 versus 63.1 ± 13.9 points ($p < 0.001$)
 - Rowe score: 96.6 ± 4.6 versus 39.9 ± 18.0 points ($p < 0.001$)
- No adverse events or anchor failures were observed

*Labral repair anchors used in this study were non-commercialised REGENESORB anchors in an OSTEORAPTOR[®] shape.

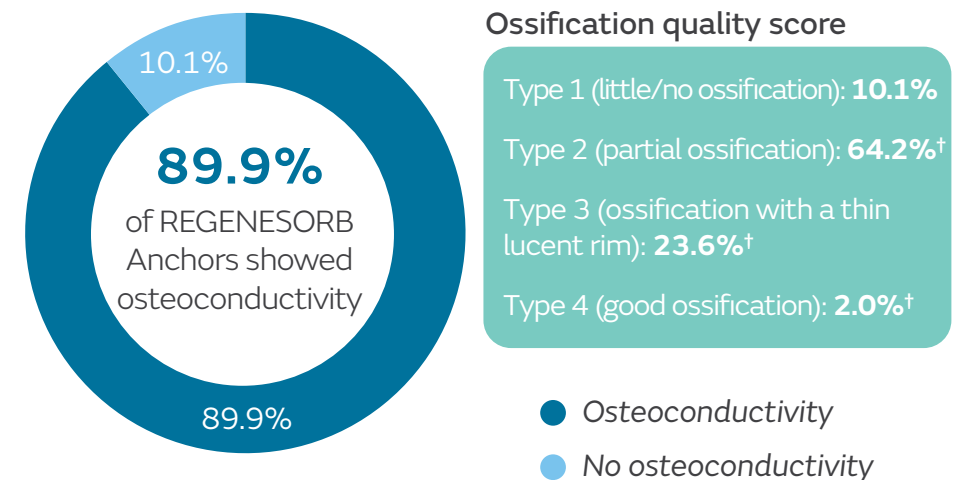



Figure. OQS scores two years post-arthroscopic labral repair

Due to rounding, the proportions of anchors in each type category do not exactly sum to total values for osteoconductivity/no osteoconductivity.
[†]Types 2, 3 and 4 are considered to display osteoconductivity according to previous studies

Conclusion

REGENESORB suture anchors used for arthroscopic labral repair demonstrated high levels of osteoconductivity and led to significant improvements in shoulder function scores compared to pre-operative values.



Osteoconductive resorption characteristics of a novel biocomposite suture anchor material in rotator cuff repair²⁰

Vonhoegen J, John D, Hägermann C. *J Orthop Surg Res.* 2019;14:12.

Overview

Retrospective study evaluating implant resorption, osteolysis, re-tear rates and pull-out complications in 48 patients receiving 82 HEALICOIL \diamond REGENESORB \diamond Suture Anchors at a mean follow-up of 21 months after rotator cuff repair

Results

- At 21 months, 79% (65/82) of anchors could not be distinguished from adjacent bone material on MRI (Figure)
- Osteolysis was detected in only 2.4% (2/82) of anchors; no reaction exceeded the diameter of the former suture anchor (5.5mm) and no peri-anchor cysts were formed
- Complete healing was achieved in 96% (46/48) of patients and no anchor pull-out complications were detected

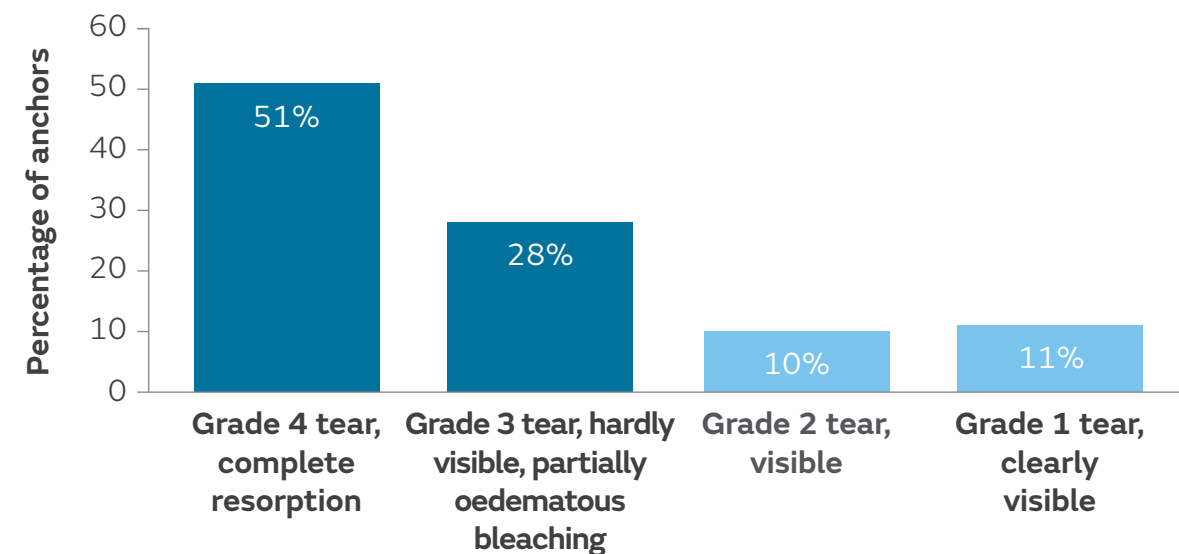


Figure. HEALICOIL REGENESORB Anchor resorption at 21 months post-operatively

Conclusion

HEALICOIL REGENESORB Anchors provide strong primary stability, reliable degradation and maintains bone quality of the rotator cuff footprint.

References

1. Arnoczky SP, Bishai SK, Schofield B, et al. Histologic evaluation of biopsy specimens obtained after rotator cuff repair augmented with a highly porous collagen implant. *Arthroscopy*. 2017;33:278–283.
2. Bokor DJ, Sonnabend D, Deady L, et al. Evidence of healing of partial-thickness rotator cuff tears following arthroscopic augmentation with a collagen implant: a 2-year MRI follow-up. *Muscles Ligaments Tendons J*. 2016;6:16–25.
3. Bokor DJ, Sonnabend DH, Deady L, et al. Healing of partial-thickness rotator cuff tears following arthroscopic augmentation with a highly-porous collagen implant: a 5-year clinical and MRI follow-up. *Muscles Ligaments Tendons J*. 2019;9:338–347.
4. Bushnell BD, Bishai SK, Krupp RJ, et al. Treatment of partial-thickness rotator cuff tears with a resorbable bioinductive bovine collagen implant: 1-year results from a prospective multicenter registry. *Orthop J Sports Med*. 2021;9:23259671211027850.
5. Camacho-Chacon JA, Cuenca-Espierrez J, Roda-Rojo V, et al. Bioinductive collagen implants facilitate tendon regeneration in rotator cuff tears. *J Exp Orthop*. 2022;9:53.
6. Ruiz Ibán MA, Navlet MG, Marco SM, et al. Augmentation of a transosseous equivalent repair in posterosuperior non-acute rotator cuff tears with a bioinductive collagen implant decreases the re-tear rate at one year. A randomised controlled trial. *Arthroscopy*. 2023 Dec 28. [Epub ahead of print]
7. Schlegel TF, Abrams JS, Angelo RL, Getelman MH, Ho CP, Bushnell BD. Isolated bioinductive repair of partial-thickness rotator cuff tears using a resorbable bovine collagen implant: two-year radiologic and clinical outcomes from a prospective multicenter study. *J Shoulder Elbow Surg*. 2021;30:1938–1948.
8. Thon SG, O'Malley L 2nd, O'Brien MJ, Savoie FH 3rd. Evaluation of healing rates and safety with a bioinductive collagen patch for large and massive rotator cuff tears: 2-year safety and clinical outcomes. *Am J Sports Med*. 2019;47:1901–1908.
9. Bokor DJ, Sonnabend D, Deady L, et al. Preliminary investigation of a biological augmentation of rotator cuff repairs using a collagen implant: a 2-year MRI follow-up. *Muscles Ligaments Tendons J*. 2015;5:144–150.
10. Bushnell BD, Connor P, Harris HW, Ho CP, Trenhaile SW, Abrams JS. Two-year outcomes with a bioinductive collagen implant used in augmentation of arthroscopic repair of full-thickness rotator cuff tears: final results of a prospective multi-center study. *J Shoulder Elbow Surg*. 2022 Jul 1. [Epub ahead of print]
11. Dai A, Campbell A, Bloom D, Baron S, Begly J, Meislin R. Collagen-based bioinductive implant for treatment of partial thickness rotator cuff tears. *Bull Hosp Jt Dis*. 2020;78:195–201.
12. McIntyre LF, Bishai SK, Brown PB 3rd, Bushnell BD, Trenhaile SW. Patient-reported outcomes after use of a bioabsorbable collagen implant to treat partial and full-thickness rotator cuff tears. *Arthroscopy*. 2019;35:2262–2271.
13. McIntyre LF, McMillan S, Trenhaile SW, Bishai SK, Bushnell BD. Full-thickness rotator cuff tears can be safely treated with a resorbable bioinductive bovine collagen implant: one-year results of a prospective, multicenter registry. *Arthrosc Sports Med Rehabil*. 2021;3:e1473–e1479.
14. Chahla J, Liu JN, Manderle B, et al. Bony ingrowth of coil-type open-architecture anchors compared with screw-type PEEK anchors for the medial row in rotator cuff repair: a randomized controlled trial. *Arthroscopy*. 2020;36:952–961.
15. Clark TR, Guerrero EM, Song A, O'Brien MJ, Savoie FH. Do vented suture anchors make a difference in rotator cuff healing. *Ann Sports Med Res*. 2016;3:1068.
16. Yamauchi S, Tsukada H, Sasaki E, et al. Biomechanical analysis of bioabsorbable suture anchors for rotator cuff repair using osteoporotic and normal bone models. *J Orthop Sci*. 2022;27:115–121.
17. Kim JH, Kim YS, Park I, et al. A comparison of open-construct PEEK suture anchor and non-vented biocomposite suture anchor in arthroscopic rotator cuff repair: a prospective randomized clinical trial. *Arthroscopy*. 2020;36:389–396.
18. Sano H, Tokunaga M, Noguchi M, et al. Comparison of fixation properties between coil-type and screw-type anchors for rotator cuff repair: a virtual pullout testing using 3-dimensional finite element method. *J Orthop Sci*. 2016;21:452–457.
19. Sugaya H, Suzuki K, Yoshimura H, et al. Osteointegration of a biocomposite suture anchor after arthroscopic shoulder labral repair. *Arthroscopy*. 2019;35:3173–3178.
20. Vonhoegen J, John D, Hägermann C. Osteoconductive resorption characteristics of a novel biocomposite suture anchor material in rotator cuff repair. *J Orthop Surg Res*. 2019;14:12.
21. Bushnell BD, Connor PM, Harris HW, Ho CP, Trenhaile SW, Abrams JS. Retear rates and clinical outcomes at 1 year after repair of full-thickness rotator cuff tears augmented with a bioinductive collagen implant: a prospective multicenter study. *JSES Int*. 2021;5:228–237.

References

22. Micheloni GM, Salmaso G, Zecchinato G, Giaretta S, Barison E, Momoli A. Bio-inductive implant for rotator cuff repair: our experience and technical notes. *Acta Biomed*. 2020;91:e2020004.
23. Schlegel TF, Abrams JS, Bushnell BD, Brock JL, Ho CP. Radiologic and clinical evaluation of a bioabsorbable collagen implant to treat partial-thickness tears: a prospective multicenter study. *J Shoulder Elbow Surg*. 2018;27:242–251.
24. Van Kampen C, Arnoczky S, Parks P, et al. Tissue-engineered augmentation of a rotator cuff tendon using a reconstituted collagen scaffold: a histological evaluation in sheep. *Muscles Ligaments Tendons J*. 2013;3:229–235.
25. Rashid MS, Cooper C, Cook J, et al. Increasing age and tear size reduce rotator cuff repair healing rate at 1 year. *Acta Orthop*. 2017;88:606–611.
26. Lo IK, Burkhart SS. Transtendon arthroscopic repair of partial-thickness, articular surface tears of the rotator cuff. *Arthroscopy*. 2004;20:214–220.
27. Millett PJ, Wilcox RB, O'Holleran JD, Warner JJP. Rehabilitation of the rotator cuff: an evaluation-based approach. *J Am Acad Orthop Surg*. 2006;14:599–609.
28. Arai E, Nakashima H, Tsukushi S, et al. Regenerating the fibula with beta-tricalcium phosphate minimizes morbidity after fibula resection. *Clin Orthop Relat Res*. 2005:233–237.
29. Chu C-C. Biodegradable polymeric biomaterials: an updated overview. In: Bronzino JD, ed. *The biomedical engineering handbook*. CRC Press; 1995:Section IV:44.
30. Calori GM, Mazza E, Colombo M, Ripamonti C. The use of bone-graft substitutes in large bone defects: any specific needs? *Injury*. 2011;42(SUPP 2):S56–S63.
31. Costantino PD, Friedman CD. Synthetic bone graft substitutes. *Otolaryngol Clin North Am*. 1994;27:1037–1074.
32. Gaasbeek RD, Toonen HG, van Heerwaarden RJ, Buma P. Mechanism of bone incorporation of beta-TCP bone substitute in open wedge tibial osteotomy in patients. *Biomaterials*. 2005;26:6713–6719.
33. Park K, Skidmore S, Hadar J, et al. Injectable, long-acting PLGA formulations: Analyzing PLGA and understanding microparticle formation. *J Control Release*. 2019;304:125–134.
34. Walsh WR, Morberg P, Yu Y, et al. Response of a calcium sulfate bone graft substitute in a confined cancellous defect. *Clin Orthop Relat Res*. 2003:228–236.
35. Smith+Nephew 2010. Micro-CT and histological evaluation of specimens from resorbable screw study (RS-II / OM1-08) 24-month post-implantation. Internal Report WRP-TE045-700-08.
36. Smith+Nephew 2016. Healicoil Regenesorb Suture Anchor – a study to assess implant replacement by bone over a 2 year period. NCS248.
37. Milewski MD, Diduch DR, Hart JM, Tompkins M, Ma S-Y, Gaskin CM. Bone replacement of fast-absorbing biocomposite anchors in arthroscopic shoulder labral repairs. *Am J Sports Med*. 2012;40:1392–1401.
38. Sgroi M, Friesz T, Schocke M, Reichel H, Kappe T. Biocomposite suture anchors remain visible two years after rotator cuff repair. *Clin Orthop Relat Res*. 2019;477:1469–1478.
39. Duralde XA. CORR Insights®: Biocomposite suture anchors remain visible two years after rotator cuff repair. *Clin Orthop Relat Res*. 2019;477:1479–1481.

Abbreviations

3D-FEM	3-dimensional finite element method	PT	partial-thickness
ASES	American Shoulder and Elbow Surgeons	SANE	single-assessment numeric evaluation
CI	confidence interval	SD	standard deviation
CMS	Constant-Murley Score	SECEC	Société Européenne pour la Chirurgie de l'Epaule et du Coude (European Society for Surgery of the Shoulder and the Elbow)
CT	computerised tomography	SEM	standard error of the mean
FT	full-thickness	Ti	titanium
HRQoL	health-related quality of life	VAS	visual analogue scale
JSS-SIS	Japanese Shoulder Society shoulder instability score	VR-12 MCS	Veterans RAND 12-Item Health Survey Mental Component Score
MCID	minimal clinically important difference	VR-12 PCS	Veterans RAND 12-Item Health Survey Physical Component Score
MRI	magnetic resonance imaging	WORC	Western Ontario Rotator Cuff Index
N	Newton	β-TCP	β-tricalcium phosphate
OQS	Ossification Quality Score		
PLGA	poly L-lactic-co-glycolic acid		
PROM	patient-reported outcome measure		

Sports Medicine,
Smith & Nephew, Inc.
150 Minuteman
Road, Andover, MA
01810, USA.

www.smith-nephew.com

◇Trademark of Smith+Nephew
All Trademarks acknowledged

© 2024 Smith+Nephew
18764 V5 02/24. Published February 2024.

Developed by Evidence Communications,
Global Clinical & Medical Affairs

Smith+Nephew