

Smith+Nephew

SILICONE MCP

Joint Replacement

Surgical Technique




Table of contents

Introduction

System overview 2

Surgical technique

Preoperative assessment 2

Step 1 ▪ Initial incision and joint exposure 3

Step 2 ▪ Opening the Metacarpal Medullary Canal 3

Step 3 ▪ Establishing Metacarpal Medullary Canal alignment 3

Step 4 ▪ Metacarpal Osteotomy 4

Step 5 ▪ Opening the Phalangeal Medullary Canal 4

Step 6 ▪ Establishing Phalangeal Medullary Canal alignment 5

Step 7 ▪ Phalangeal Osteotomy 5

Step 8 ▪ Phalangeal Medullary Canal Broaching 6

Step 9 ▪ Metacarpal Medullary Canal Broaching 7

Step 10 ▪ Trial insertion and reduction 8

Step 11 ▪ Implantation 9

Step 12 ▪ Final reduction and soft tissue closure 9

Step 13 ▪ Closure 9

Postoperative care 9

Warnings and precautions 10

Ordering information and implant dimensions 11

Instrumentation 12

Notes 13

System overview

The SILICONE MCP is part of an MCP system featuring two implant options that utilize the same instrumentation a two-component, anatomically designed PyroCarbon total joint replacement and a one-piece silicone spacer consisting of proximal and distal intramedullary stems and a central flexible hinge. The SILICONE MCP is recommended when the total joint cannot be used, such as with late stage rheumatoid patients. Both implants are available in 6 sizes and use the same color-coded instrumentation, providing an intraoperative choice. Components are press-fit, eliminating the need for cement. Successful use of these implants depends on proper patient selection, surgical technique, and postoperative therapy.

Surgical technique

Preoperative assessment

SILICONE MCP arthroplasty is appropriate for patients with osteo, post-traumatic and rheumatoid arthritis. In patients with rheumatoid arthritis, soft tissue imbalance may be more severe, and the surgeon must determine that correction of volar subluxation deformities and ulnar deviation deformities can be achieved with standard MCP reconstruction techniques. In patients with severe intercarpal supination and radial deviation of the wrist, ulnar deviation of the digits may not be correctable with soft tissue surgery and in these instances, it is recommended that corrective wrist surgery be performed first at a separate setting. Standard AP, lateral and oblique X-rays should be used to template the size of the prosthesis likely to be required at surgery.

Note Bena

The following technique is for informational and educational purposes only. It is not intended to serve as medical advice. It is the responsibility of treating physicians to determine and utilize the appropriate products and techniques according to their own clinical judgment for each of their patients. For more information on the product, including its indications for use, contraindications, and product safety information, please refer to the product's label and the Instructions for Use packaged with the product.

Prior to performing this technique, please consult the Instructions for Use documentation provided with each device for additional health and safety information, including indications, contraindications, warnings and precautions.

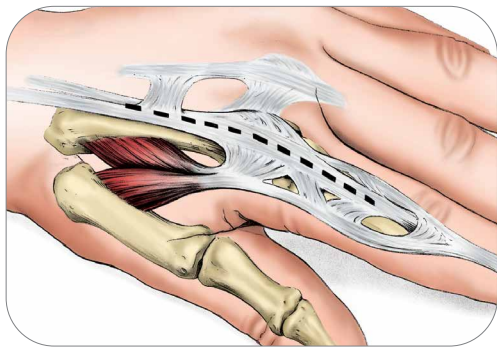


Figure 1-1

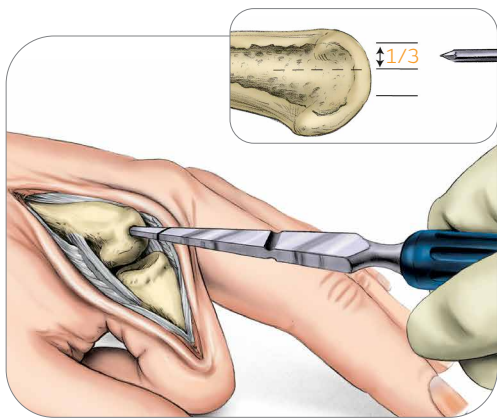


Figure 2-1

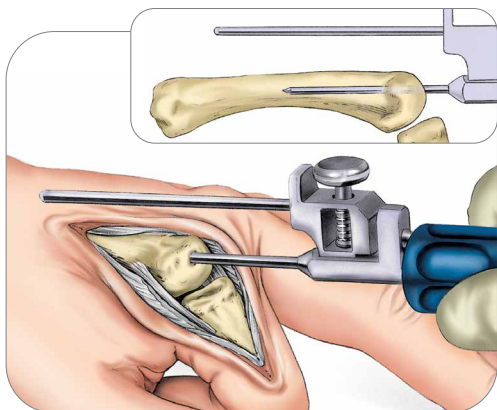


Figure 3-1

Step 1 • Initial incision and joint exposure

1-1 Make a longitudinal incision over the dorsum of the metacarpophalangeal (MCP) joint. Split the capsule longitudinally and dissect to expose the joint, preserving the capsule as much as possible for later repair. Continue the dissection so that the dorsal base of the proximal phalanx and the metacarpal head with the collateral ligaments are visualized. The metacarpal head is removed to gain access to phalangeal head which is cut, broached and sized prior to the metacarpal.

Step 2 • Opening the Metacarpal Medullary Canal

2-1 Flex finger to expose the head of the metacarpal. Use a K-wire to make the initial entry point in the metacarpal head confirming alignment on X-ray.

Entry point is made in the dorsal 1/3 of the metacarpal head and centered across the width of the head. Remove K-wire and open with starter awl rotating 360° with the cutting edge until the laser mark is reached. The opening should be aligned with the long axis of the metacarpal's medullary canal.

Step 3 • Establishing Metacarpal Medullary Canal Alignment

3-1 Attach the Alignment Guide to the Alignment Awl. Insert the Alignment Awl into the initial entry point.

Advance into the medullary canal 1/2 to 2/3 the length of the metacarpal. The Alignment Guide should be parallel to the dorsal surface of the metacarpal and in line with the long axis

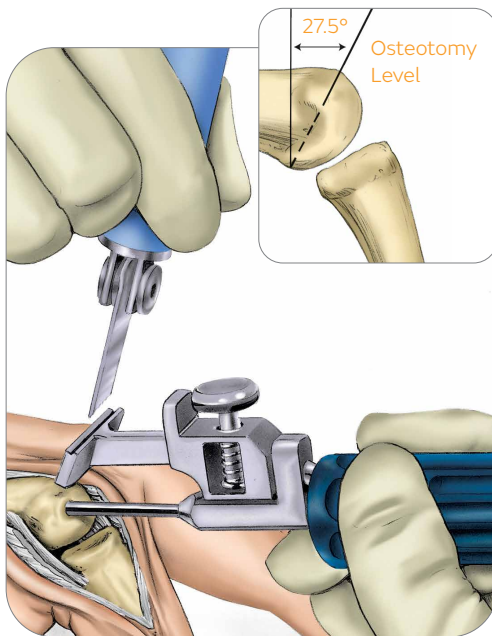


Figure 4-1

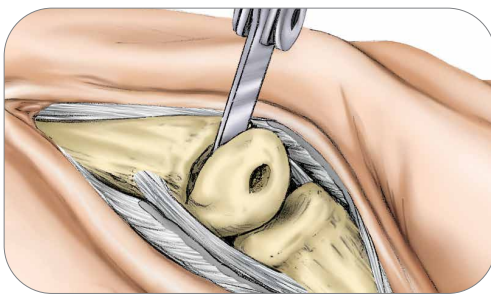


Figure 4-2

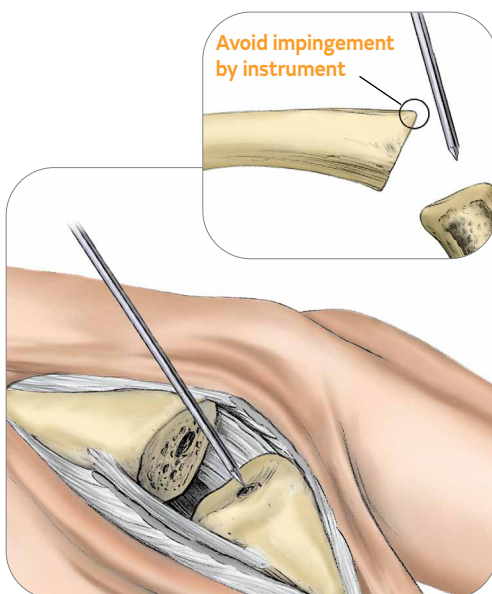


Figure 5-1

Step 4 • Metacarpal Osteotomy

4-1 Remove Alignment Guide and place the Proximal Cutting Guide on the Awl. The Cutting Guide provides a 27.5° distal back cut. Advance the Cutting Guide 1.0-2.0mm distal to the dorsal attachments of the collateral ligaments near the cortical-chondral junction. Withdraw or advance the Awl into position, holding steady to avoid toggling. The Cutting Guide should be parallel to the surface of the metacarpal bone. Position the saw blade in the Cutting Guide slot and create the initial cut until the rod of the Alignment Awl is reached.

Surgical pearls

- Use of a small oscillating saw blade (7mm x 29.5mm x 0.4mm), such as that in the MCP disposable pack provided, is recommended to perform the osteotomy.
- Test correct positioning by sliding blade through the cutting guide slot before initiating the saw. The proximal cut should be 1.0-2.0mm distal to the collateral ligaments. Articular cartilage left behind does not need to be removed from the articular head.
- An initial conservative osteotomy allows for alterations and joint space adjustments during trial insertion.

Step 4 • Metacarpal Osteotomy (continued)

4-2 Remove the Alignment Awl and complete the osteotomy freehand by following the previously established plane.

Step 5 • Opening the Phalangeal Medullary Canal

Caution: Flex the joint to avoid damage, by impingement of the K-wire or Starter Awl, to the dorsal edge of the metacarpal osteotomy.

5-1 Use a K-wire to make the initial entry point in the proximal phalanx confirming alignment on X-ray. The entry point is made in the dorsal 1/3 of the base of the proximal phalanx and centered across the width of the base. Remove the K-wire and open with the starter awl rotating 360° with the cutting edge until the laser mark is reached. The opening should be aligned with the long axis of the phalanx's medullary canal.

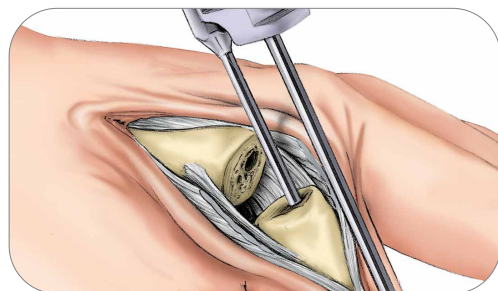


Figure 6-1

Step 6 • Establishing Phalangeal Medullary Canal Alignment

6-1 Mount the Alignment Guide on the Alignment Awl and flex the joint. Insert and advance the Alignment Awl into the proximal phalangeal medullary canal approximately 1/2 to 2/3 the length of the phalanx. The Alignment Guide should be parallel to the dorsal surface of the phalanx and in line with the long axis of the bone.

Step 7 • Phalangeal Osteotomy

7-1 Remove Alignment Guide and place the Distal Cutting Guide on to the awl. The Cutting Guide provides a 5° distal back cut. Advance the Cutting Guide 0.5-1.0mm proximal to the collateral ligament attachments. Advance the awl into position.

The Cutting Guide should be parallel to the surface of the phalanx. Position saw blade in the Cutting Guide slot and create the initial cut until the rod of the Alignment Awl is reached.

Surgical pearls

- Test correct positioning by sliding blade through cutting guide slot before initiating the saw. The distal cut should remove only the articular surface.
- If the proximal phalanx is badly deformed or deficient dorsally, the cut may need to be done free hand.

7-2 Remove the Alignment Awl and complete the osteotomy freehand by following the previously established plane.

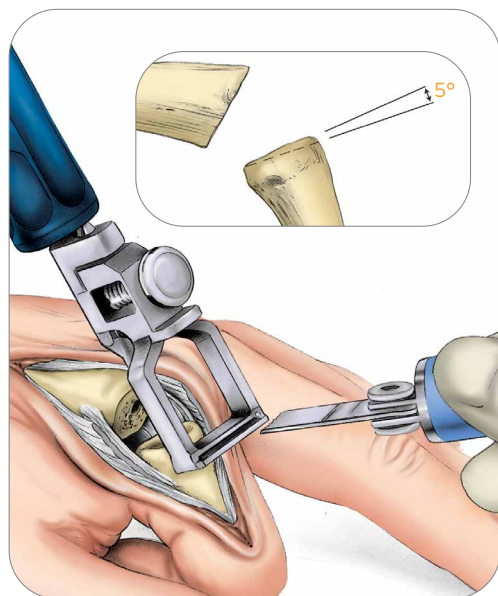


Figure 7-1

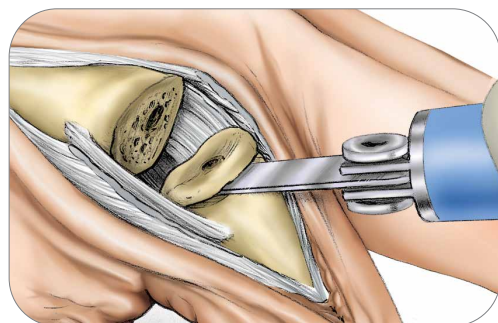


Figure 7-2

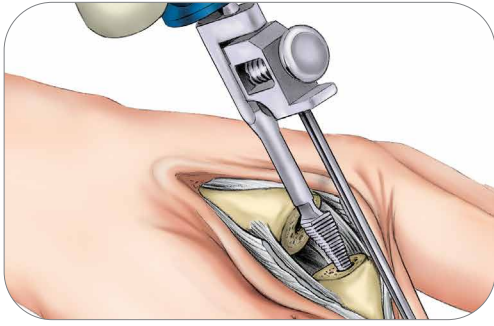


Figure 8-1

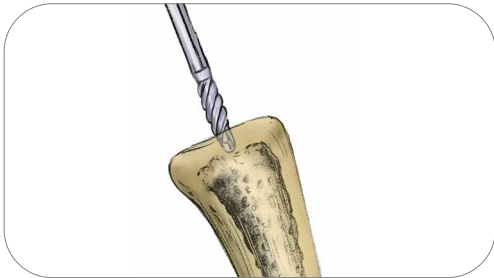

Figure 8-2

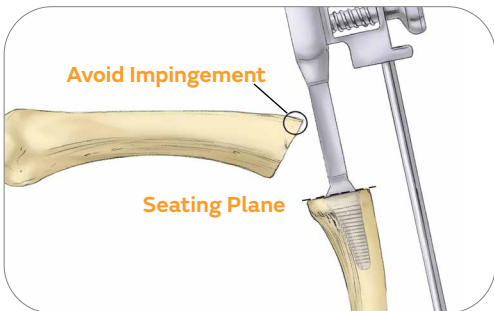


Figure 8-3

Step 8 - Phalangeal Medullary Canal Broaching

8-1 After an entry way is made to allow insertion of the Size 10 Distal Broach, the canal is broached. The goal is to insert the largest implant possible while maintaining a centralized alignment within the canal.

8-2 A burr can be used to remove remaining cortical bone at the opening of the canal. Sculpt opening in the shape of the broach. Do not use burr within the intramedullary canal. It is important to minimize burring within the canal as this will disrupt the press fit of the implant and may damage the endosteal bone. Overheating the bone is to be avoided at all costs. It is strongly suggested to use irrigation while utilizing powered burrs.

8-3 Begin with the smallest size Distal Broach with the Alignment Guide attached and insert it halfway into the medullary canal. Proper positioning is confirmed with lateral and AP X-rays. If you notice any malalignment, remove the Broach and correct positioning with a side-cutting bur. Re-insert the Broach and confirm position with X-ray. Once proper position is confirmed, the canal may be sequentially enlarged with the broaches until the final broach rests flush to 1mm below the osteotomy level. Incomplete or partial insertion of the Broach should be corrected before the Trial is inserted.

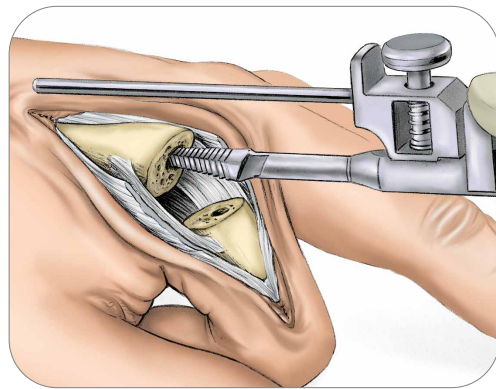


Figure 9-1

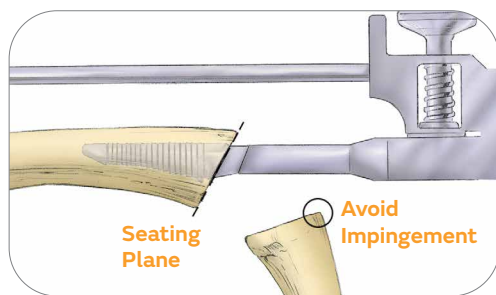


Figure 9-2

Step 9 - Metacarpal Medullary Canal Broaching

9-1 The goal is to fill the medullary canal with the same size broach that was used on the proximal phalanx while maintaining centralized alignment within the canal. Be sure to evaluate both the AP and Lateral views on the X-ray before proceeding to the next Broach to ensure proper positioning.

With the Alignment Guide attached, begin with the smallest size Broach and insert it halfway into the medullary canal. Proper positioning is confirmed with lateral and AP X-rays. If you notice any malalignment, remove the broach and correct positioning. Re-insert the Broach and confirm position with X-ray.

9-2 Continue upsizing the Broach size until you have matched the broach size used in the proximal phalanx. The final Broach should be seated flush to 1mm below the edge of the osteotomy. Incomplete or partial insertion of the Broach should be corrected prior to Trial insertion.

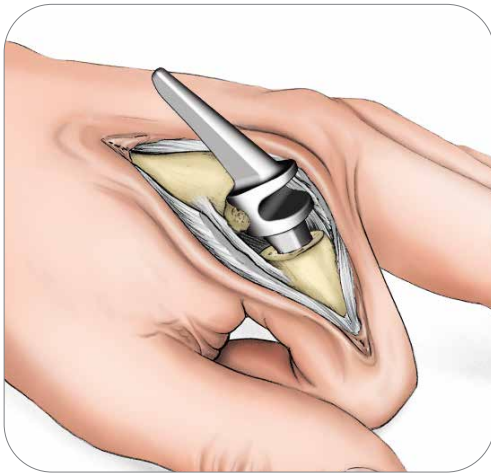


Figure 10-1

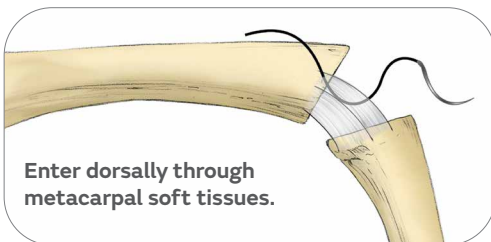


Figure A

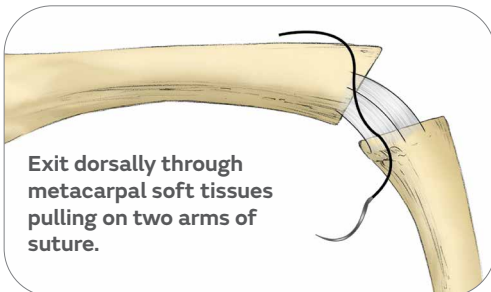


Figure B

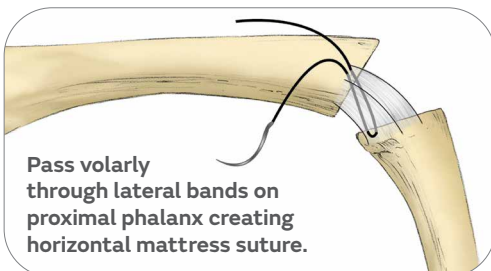


Figure C

Step 10 • Trial insertion and reduction

The color-coded silicone Trials produce the same fit as the final component. Flex the joint. Insert the silicone Trial, distal stem first until the collars seat against the bones. Reduce the joint and assess stability, joint laxity, and range of motion. Full extension of the joint should be possible.

To improve extension or relieve tension, increase the depth of the osteotomies to increase the joint space. Generally the metacarpal osteotomy should be adjusted first. Mount the osteotomy guide on the appropriate broach and reinsert in the canal to make an adjustment cut. Remove bone in small increments to avoid joint laxity or instability. Reinsert the trial. Reduce the joint and assess stability, joint laxity, and range of motion. After a satisfactory reduction, use a pick-up to remove the trial.

Surgical Pearl

If a lax joint is encountered: Ensure you have selected the largest size implant that can fit into the medullary canals. Occasionally, a larger implant may be placed by enlarging the intramedullary canal, either proximally or distally, with a burr. If stability is not obtained with a larger implant, closely examine the collateral ligament insertion site.

These ligaments may have been inadvertently damaged during the osteotomy process. If collateral ligament stability has been compromised, a collateral ligament stitch will be required to re-establish lateral stability. Collateral ligament stabilizing sutures may be useful at the MCP joint where there is joint laxity. It is recommended to use this suture for every patient with RA.

Collateral Ligament Suture

Adequate soft tissue is usually found at the dorsal portion of the metacarpal bone in the vicinity of the accessory collateral ligament. Distally, the insertion areas of the collateral ligament are usually sufficient to support a strong suture. If adequate soft tissue purchase is not possible with a standard suture, a drill hole prepared with a .045" K-wire can be utilized to pass suture through bone for fixation. The drill holes may be created at the lateral margins of the metacarpal and proximal phalanx.

The suture should be placed before the implant is inserted.

A strong "0" absorbable suture (such as Dexon or Vicryl) with a large non-cutting needle should be used. The suture is passed in a horizontal mattress fashion dorsally through metacarpal soft tissues (**Figure A**) and then through the proximal phalanx volarly exiting external to the lateral bands (**Figure B**).

The two arms of the suture are individually pulled dorsally and proximally (**Figure C**). If properly placed, the sutures will pull the proximal phalanx to either the respective radial or ulnar direction, and the proximal phalanx will be pulled up to the metacarpal. If the proximal phalanx is not angulated with closure of the joint space by the individual radial and ulnar sutures, the sutures need to be replaced.

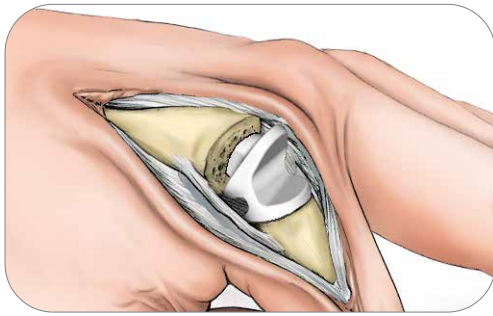


Figure 11-1

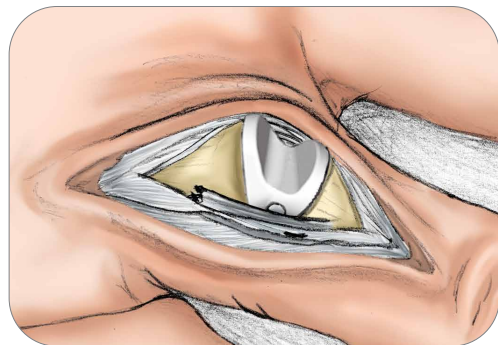


Figure 12-1

Step 11 • Implantation

11-1 With the joint flexed, insert the final implant, distal stem first, until the collars seat against the bones.

Step 12 • Final reduction and soft tissue closure

12-1 Reduce the joint. Recheck stability, joint axial alignment and range of motion of the components, which should mimic the performance of the trial components. Full digit extension should be possible. If collateral ligament suture has been placed, the radial collateral ligament suture is tied tightly with the MCP fully extended and slight radial deviation.

The ulnar suture is then tied into position with the finger held in the same radial deviated position. Tighten the soft tissue envelope with a capsular repair to provide support and prevent volar subluxation/dislocation of the implant.

Step 13 • Closure

The extensor tendon must be centralized and snug, which can be accomplished by imbrication of the radial hood under the ulnar side of the central tendon then repairing the radial side central tendon to the radial hood. Occasionally, the central tendon can be advanced and sutured into the dorsal base of the phalanx to increase stability of the implant against volar subluxation.

At the conclusion of closure and application of the dressing, take X-rays to confirm the correct implant position.

Post-operative care*

Place the hand in a bulky dressing. If possible, maintain the wrist at 10-15° of dorsiflexion and slight ulnar deviation.

MCPs should be held in full extension and PIPs in slight flexion (5-10°).

If Swan neck deformities were present preoperatively, the PIPs should be placed in the maximum flexion possible. Use a palmar plaster splint to maintain this position, with the final wrap over the entire hand leaving the distal tips of the digits exposed during the first two days to help with edema control. Encourage active range of motion (AROM) of the shoulder and elbow.

Accepted practices for postoperative care and rehabilitation exercises for SILICONE MCP arthroplasty should be followed.

In osteoarthritic and post traumatic cases, early motion may be prescribed. For rheumatoid arthritis cases, late motion initiation may be appropriate.

*Postoperative care is individualized and is determined by the physician based on the patient's injury pattern, unique patient anatomy, and pathologic kinematics. Not all patients will have the same surgical procedure or timelines for rehabilitation. The views and opinions expressed for postoperative care are for informational and educational purposes only. Smith & Nephew, Inc. does not provide medical advice. In no event shall Smith & Nephew, Inc., be liable for any damages whatsoever (including, without limitation, damages for loss of business profits, business interruption, loss of business information, or other pecuniary loss) arising out of the use of or inability to use the expressed views.

Warnings and precautions

Warnings:

The following conditions, singularly or concurrently, tend to place excessive loads on the finger joint prosthesis and, thereby, place the patient at higher risk for failure of the prosthesis. If excessive loading of the affected finger joint cannot be prevented, this finger joint prosthesis should not be used.

- Excessive activity of the affected joint;
- Uncorrected or recurrent deformity;
- Incorrect sizing of the implant;
- Inadequate soft tissue or bony support;
- Implant malposition.

The benefits of finger joint replacement may not meet the patient's expectations or may deteriorate over time. Pain, swelling, instability, and/or deformity may persist or return after finger joint replacement.

Precautions:

Do not reuse this device. Any implant that has been damaged, mishandled, or removed from the sterile field may have surface damage that could result in implant fracture and should be discarded.

Surgical technique



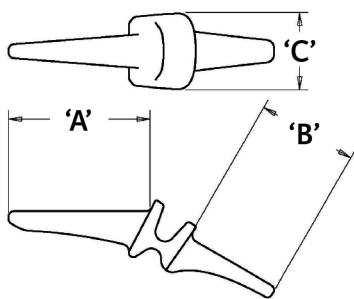
Smith+Nephew does not practice medicine and does not recommend this or any other surgical technique for use on a specific patient. The surgeon who performs any implant procedure is responsible for determining and using the appropriate techniques for implanting the device in each patient.

Ordering information and implant dimensions

Implants

| Catalog number | Description |
|-----------------|-------------------------------|
| SMCP-500-05-WW | SILICONE MCP Implant, Size 05 |
| SMCP-500-10-WW | SILICONE MCP Implant, Size 10 |
| SMCP-500-20-WW | SILICONE MCP Implant, Size 20 |
| SMCP-500-30-WW | SILICONE MCP Implant, Size 30 |
| SMCP-500-40-WW | SILICONE MCP Implant, Size 40 |
| SMCP-500-50-WW* | SILICONE MCP Implant, Size 50 |

Implant Dimensions (mm)



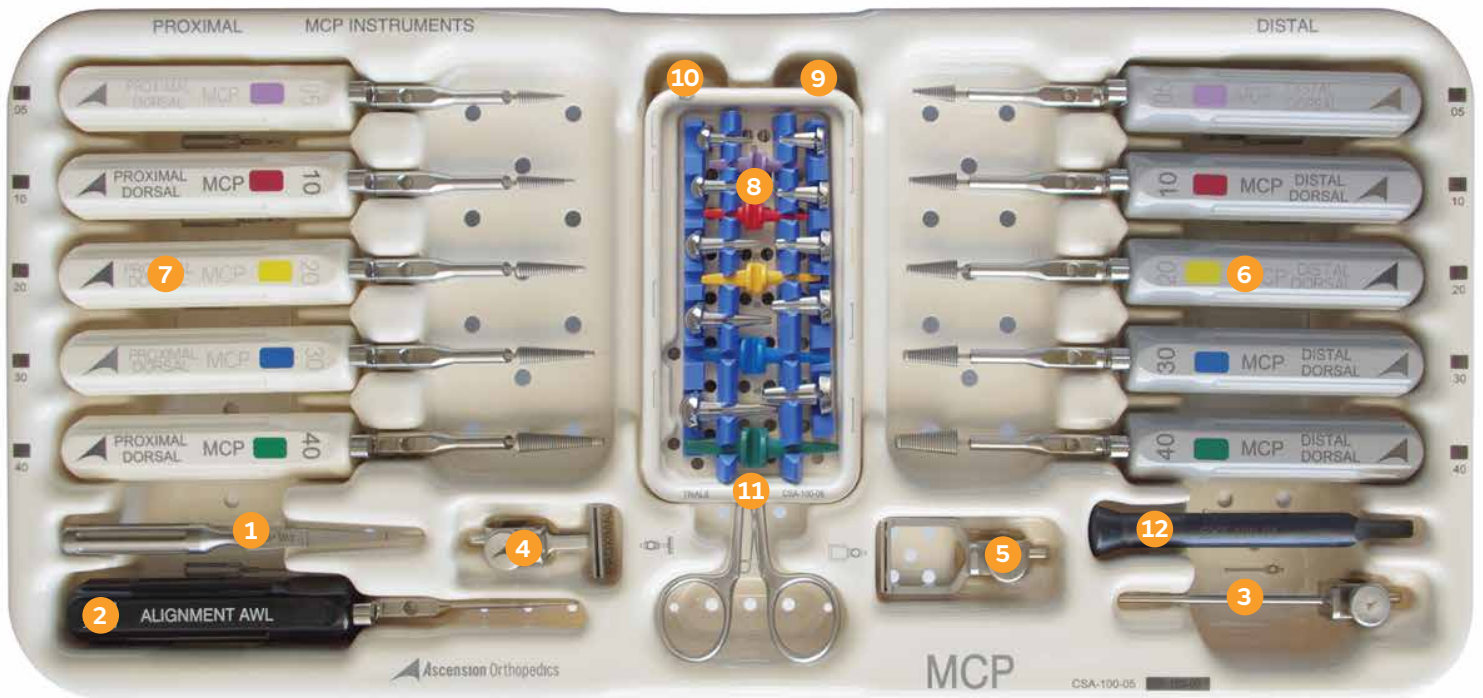
| SIZE | (A) PROXIMAL STEM LENGTH | (B) DISTAL STEM LENGTH | (C) HINGE WIDTH |
|------|--------------------------|------------------------|-----------------|
| 05 | 15.8 | 14.2 | 10.6 |
| 10 | 18.6 | 15.6 | 10.8 |
| 20 | 22.3 | 16.8 | 11.8 |
| 30 | 25.9 | 18.3 | 13.8 |
| 40 | 29.4 | 21.2 | 15.1 |
| 50* | 33.0 | 22.8 | 16.9 |

* The size 50 implants are available per special request only.

Instruments

| Catalog number | Description |
|----------------|--------------------------------------|
| CSA-000-01 | Lid (Case) |
| CSA-100-05 | MCP Base 05-40 (Case) |
| CSA-100-06 | MCP Trial Caddy 05-40 (Case) |
| IMP-100-00P | MCP Proximal Impactor |
| IMP-100-00D | MCP Distal Impactor |
| EXT-200-00 | PIP Trial Extractor |
| EXT-100-01 | MCP Implant Extractor |
| ALG-100-00 | E/M Alignment Guide |
| OSG-100-00P | MCP Proximal Osteotomy Guide |
| OSG-100-00D | MCP Distal Osteotomy Guide |
| AWL-200-00 | PIP Alignment Awl |
| AWL-100-01 | Starter Awl |
| TRL-101-10P | MCP Proximal Trial Sz. 10 (Metal) |
| TRL-101-20P | MCP Proximal Trial Sz. 20 (Metal) |
| TRL-101-30P | MCP Proximal Trial Sz. 30 (Metal) |
| TRL-101-40P | MCP Proximal Trial Sz. 40 (Metal) |
| TRL-101-05P | MCP Proximal Trial Sz. 05 (Metal) |
| TRL-101-10D | MCP Distal Trial Sz. 10 (Metal) |
| TRL-101-20D | MCP Distal Trial Sz. 20 (Metal) |
| TRL-101-30D | MCP Distal Trial Sz. 30 (Metal) |
| TRL-101-40D | MCP Distal Trial Sz. 40 (Metal) |
| TRL-101-05D | MCP Distal Trial Sz. 05 (Metal) |
| TRL-500-10 | MCP Silicone Trial Sz. 10 |
| TRL-500-20 | MCP Silicone Trial Sz. 20 |
| TRL-500-30 | MCP Silicone Trial Sz. 30 |
| TRL-500-40 | MCP Silicone Trial Sz. 40 |
| TRL-500-05 | MCP Silicone Trial Sz. 05 |
| BRH-100-10P | MCP Proximal Broach Sz. 10 |
| BRH-100-20P | MCP Proximal Broach Sz. 20 |
| BRH-100-30P | MCP Proximal Broach Sz. 30 |
| BRH-100-40P | MCP Proximal Broach Sz. 40 |
| BRH-101-05P | MCP Proximal Broach Sz. 05 (Cutting) |
| BRH-100-10D | MCP Distal Broach Sz. 10 |
| BRH-100-20D | MCP Distal Broach Sz. 20 |
| BRH-100-30D | MCP Distal Broach Sz. 30 |
| BRH-100-40D | MCP Distal Broach Sz. 40 |
| BRH-101-05D | MCP Distal Broach Sz. 05 (Cutting) |

Instrumentation



1. Starter Awl
2. Alignment Awl
3. Alignment Guide
4. Proximal Osteotomy Guide
5. Distal Osteotomy Guide
6. Distal Broaches
7. Proximal Broaches
8. Trials
9. Distal Impactor
10. Proximal Impactor
11. Trial Extractor
12. Implant Extractor

Notes

Notes

Products may not be available in all markets because product availability is subject to the regulatory and/or medical practices in individual markets. Please contact your Smith+Nephew representative or distributor if you have questions about the availability of Smith+Nephew products in your area.

Smith & Nephew, Inc.
1450 Brooks Road
Memphis, TN 38116
USA

www.smith-nephew.com
T: 1-901-396-2121
Orders and Inquiries: 1-800-238-7538

[®]Trademark of Smith+Nephew.
All trademarks acknowledged.
©2022 Smith+Nephew. All rights reserved.
31781 V2 LC-04-507-001 REVI 09/22

Manufacturer:



Ascension Orthopedics, Inc
11101 Metric Blvd
Austin, TX 78758 • USA