

+ Evidence in focus

Publication summary: Moriarty P, et al. *Arch Orthop Trauma Surg* (2021)*

Smith+Nephew

The REDAPT[◇] Femoral Revision System demonstrates favourable early clinical, radiological and patient-reported outcomes in revision total hip arthroplasty (rTHA)

+ Plus points

Osseous restoration in
11/19



of proximal femurs;
0 stress shielding



No clinically significant subsidence (>10 mm)



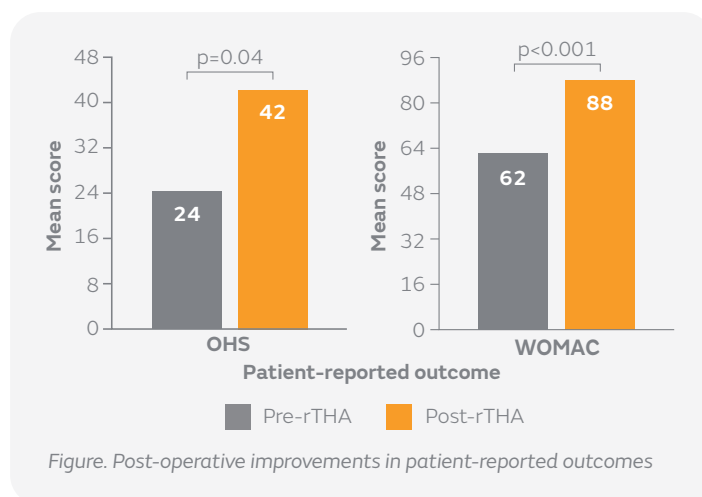
Significant improvements in OHS (p=0.04) and WOMAC score (p<0.001)

Overview

- Retrospective review of prospectively collected data carried out at a single UK institution over a 36-month period
- Forty-three femoral revisions were performed using the REDAPT revision stem
 - Mean age was 77 years, ranging from 52 to 90 years
 - One patient was lost to clinical follow-up due to relocation
- Primary outcomes included Oxford Hip Score (OHS), Western Ontario and McMaster Universities Osteoarthritis Index (WOMAC) score and implant survivorship
- Secondary outcomes included subsidence and proximal femoral osseous remodelling

Results

- After a mean follow-up of 24 months, REDAPT demonstrated 100% survivorship
 - No stem fractures
 - Two dislocations (4.6%) were encountered (one with pre-existing instability and one with Ehlers-Danlos syndrome)
- Osseous restoration of the proximal femur was noted in 11/19 (58%) hips at 1-year follow-up
- No cases of clinically significant subsidence (>10 mm) were observed
- Heterotopic ossification was noted in eight cases (Brooker 1, n=4; Brooker 2, n=3; Brooker 3, n=1)
- Patients reported significant post-operative improvements in mean OHS and WOMAC scores (n=42; Figure)



Conclusions

The REDAPT revision stem demonstrated 100% survivorship, no stem fractures and a low dislocation rate after 2 years follow-up, with osseous restoration noted in 11/19 hips at 1 year. No cases of clinically significant subsidence were observed and patients reported significant improvements in mean OHS and WOMAC score.

Citation

*Moriarty P, Vles G, Haddad F, Konan S. Early clinical and radiological outcomes of a new tapered fluted titanium monobloc revision stem in hip arthroplasty. *Act Orthop Trauma Surg*. 2021 Jan 24. [Epub ahead of print].

Available at: [Archives of Orthopaedic and Trauma Surgery](#)