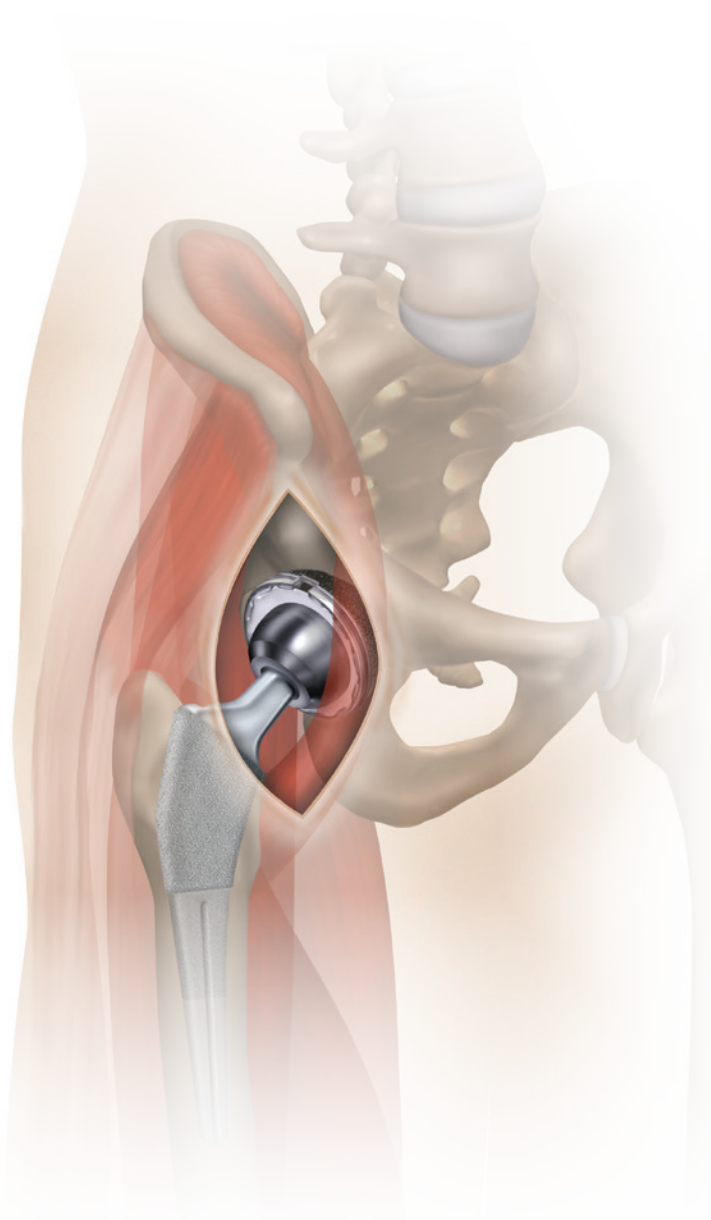


Direct Anterior approach with
a specialized operating table –
supine position



ANTHOLOGY[◇] Primary Hip System R3[◇] Acetabular System

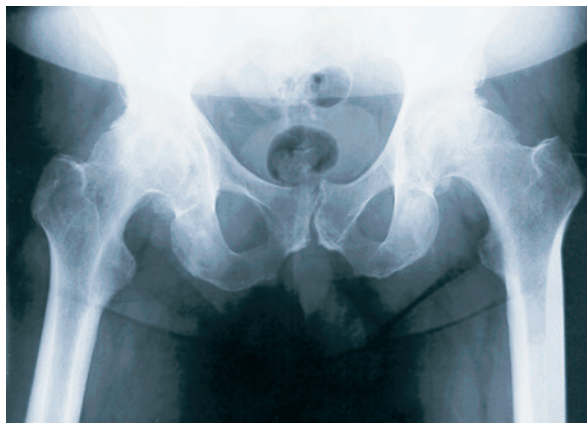Direct anterior approach surgical technique with a specialized operating table

John Masonis, MD
OrthoCarolina Hip & Knee Center, Charlotte, NC

Nota Bene

The following technique is for informational and educational purposes only. It is not intended to serve as medical advice. It is the responsibility of treating physicians to determine and utilize the appropriate products and techniques, according to their own clinical judgment, for each of their patients. For more information on the product, including its Indications for Use, contraindications, cleaning, sterilization and product safety information, please refer to the product's label and the Instructions for Use (IFU) for the product.

Surgical technique



Anteroposterior radiograph demonstrating leg length inequality

1 Preoperative planning

Preoperative templating is helpful in determining approximate sizing of the implant that is necessary for the patient. Ensure the preoperative X-ray is adequate and avoid externally rotating the femur. If needed, the contralateral hip can be templated as well.

For more information on templating, please refer to the ANTHOLOGY[®] or R3[®] surgical techniques.

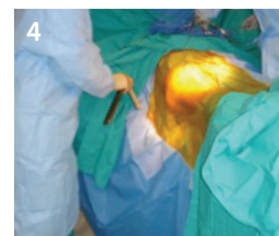
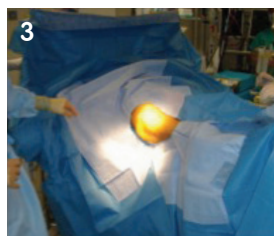
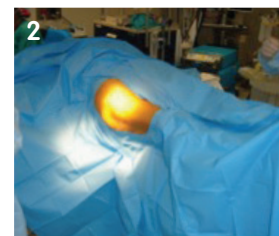
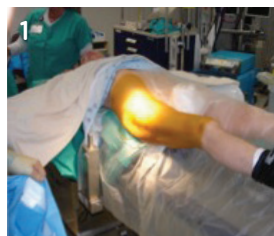Surgeon tip If the head center is between the standard and high offset, select the high offset stem, as the acetabular component is usually medialized at surgery and external rotation of the preoperative X-ray can sometimes underestimate the femoral offset.

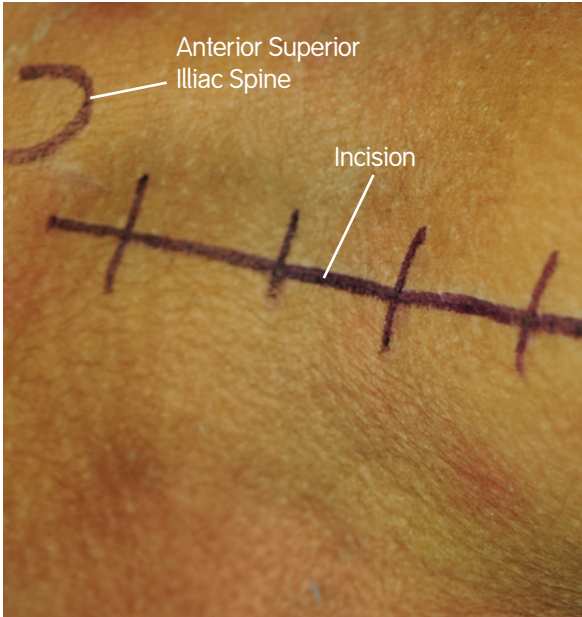

2 Positioning/prepping and draping

The patient should be placed supine on the specialized operating table. Prepare the patient's preoperative skin from the costal margin to the patella of the affected hip. Two blue, impervious U-drapes and two large split drapes are used to further drape the patient. The patient's arms should be extended outward and secured at the wrist level. Create a hole over the femoral hook adaptor post, with a scalpel, to allow for ease of insertion of the femoral hook when needed. The femoral hook lift should be located 2–5cm lateral to the patient's skin.

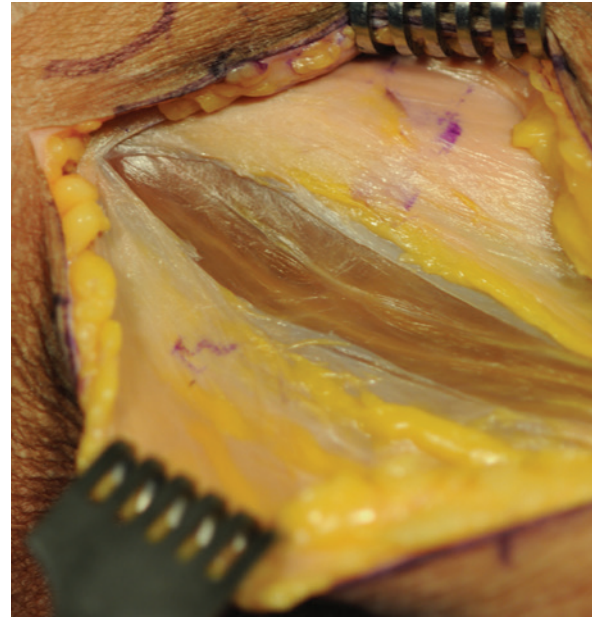
Surgeon tip Ensure that the patient's feet are secured tightly in the traction boots.





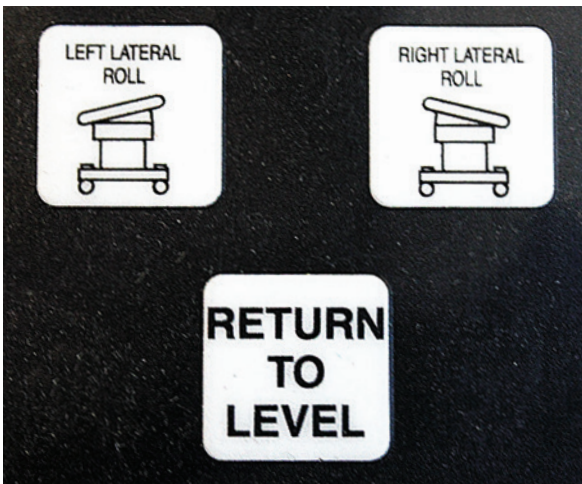3 Incision

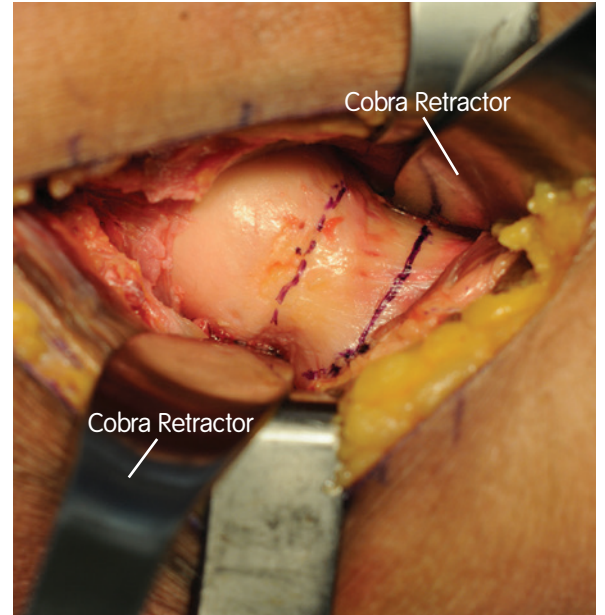
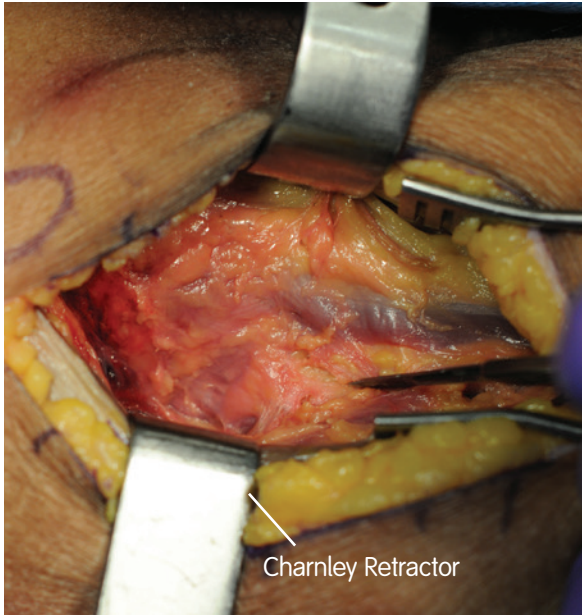
Airplaning the table away from the surgeon 10°, and with the patient's legs in neutral rotation and no traction, make a linear incision to the hip, starting 2cm posteriorly from the ASIS and extending approximately 10cm distal and lateral, until the tensor fascia lata is reached.



4 Superficial layer — Interval

After the incision is made, perform superficial dissection laterally over the tensor fascia muscle to avoid branches of the lateral femoral cutaneous nerve. Incise the tensor fascia, in line with the fibers, careful not to go into the muscle. Grasp the medial fascial border of the tensor fascia lata with a Kocher and elevate medially. Using blunt dissection, sweep the fingers between the tensor fascia lata muscle and sartorius and palpate the anterior hip capsule.





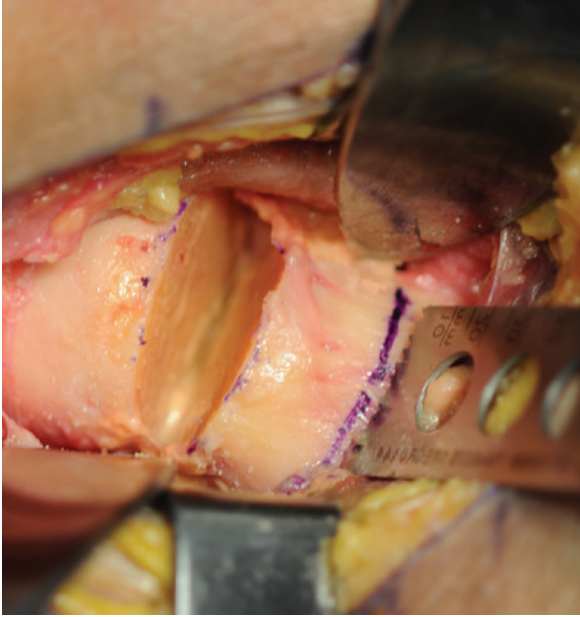
4 Superficial layer — Interval *(continued)*

Place a Charnley retractor with a medium blade lateral under the sartorius, with a long shallow blade medial, under the tensor fascia lata. Place a self-retaining retractor distal to the Charnley retractor to expose the lateral femoral circumflex vessels. Clamp the vessels and cauterize or ligate. Expose the anterior hip capsule from the reflected head of the rectus femoris to the vastus origin. Perform a linear anterolateral capsulotomy, in line with the neck, using cautery. Externally rotate the hip 60°. Perform an inverted T capsulotomy, medial and lateral, on the intertrochanteric line.

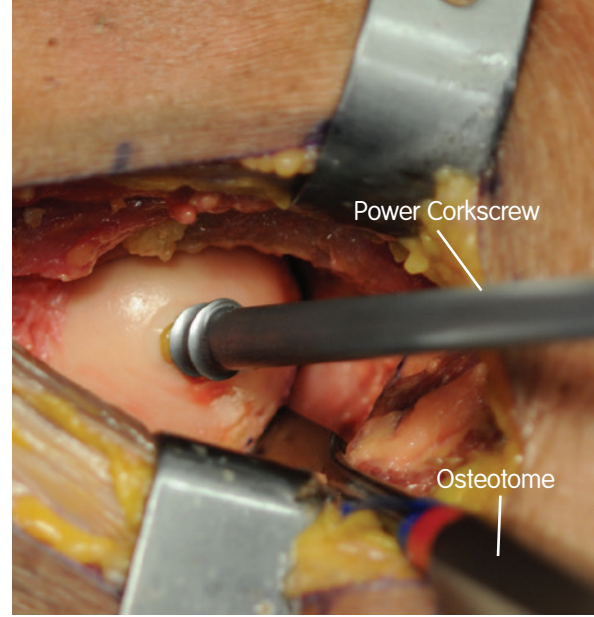
5 Osteotomy

Return the hip to 30° of external rotation prior to making the femoral osteotomy and place two turns of traction on the operative leg. Based upon preoperative radiographs and referencing the intersection between the lateral femoral neck and the greater trochanter, perform the initial, sub-capital osteotomy, 1cm above the desired level, followed by a lower neck osteotomy.





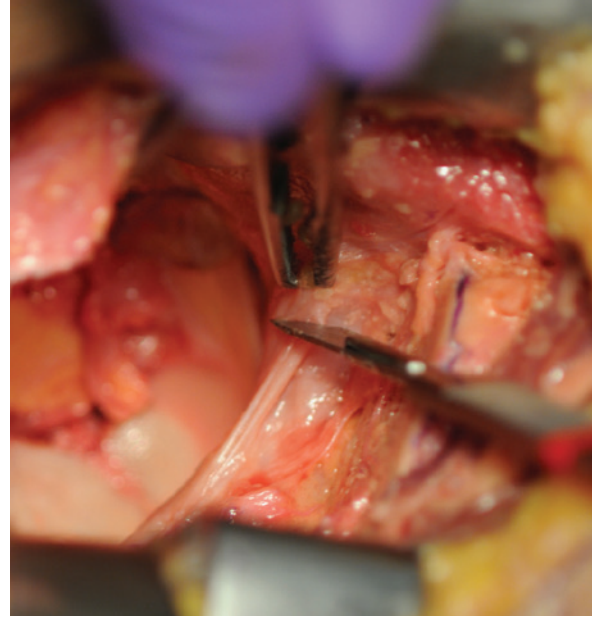
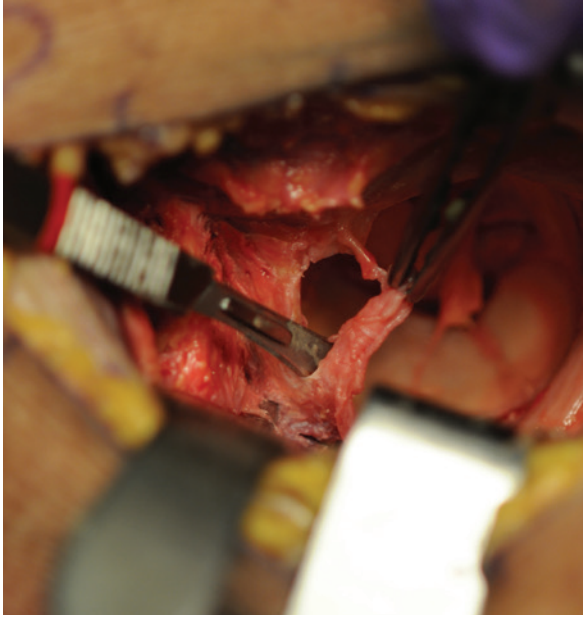
Place traction across the hip and remove the intervening napkin ring of the osteotomy. Place a curved, pointed, retractor in the superior, posterior location of the acetabulum. A bent, sharp Hohmann is then placed anteriorly.



Utilize the power corkscrew, aiming lateral to medial, to remove the femoral head.

Surgeon tip Do not directly saw, laterally, into the greater trochanter. Make sure both cuts are complete with an osteotome.



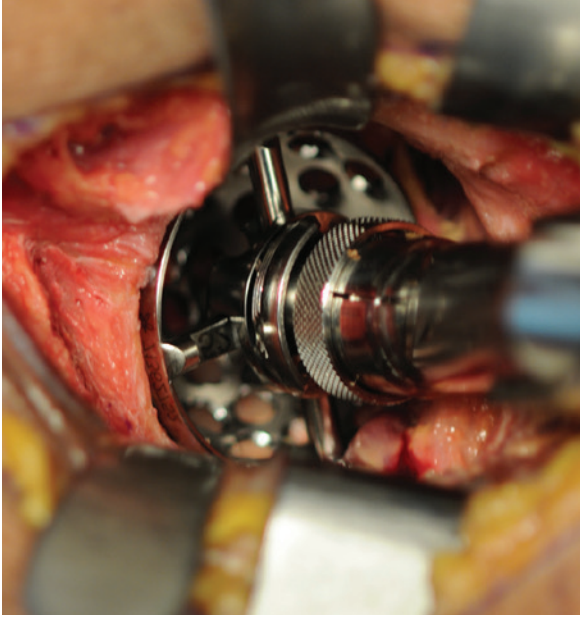


6 Acetabular preparation

Place a posterior retractor over the posterior wall and excise the posterior labrum using a long scalpel. Externally rotate the leg to 120°. Identify the posterior capsule and perform a linear capsulotomy, inside out, with cautery. A capsulectomy is not necessary. Return the leg to 60° of external rotation. Place the anterior retractor over the anterior wall and elevate the operative leg 20°. Perform an anterior labrectomy with scalpel and return the leg to neutral flexion and 45° of external rotation. Identify and radially divide the inferior capsule to the transverse acetabular ligament and insert a retractor inferiorly.

Surgeon tip To clear the calcar, traction can be added to the femur if needed.

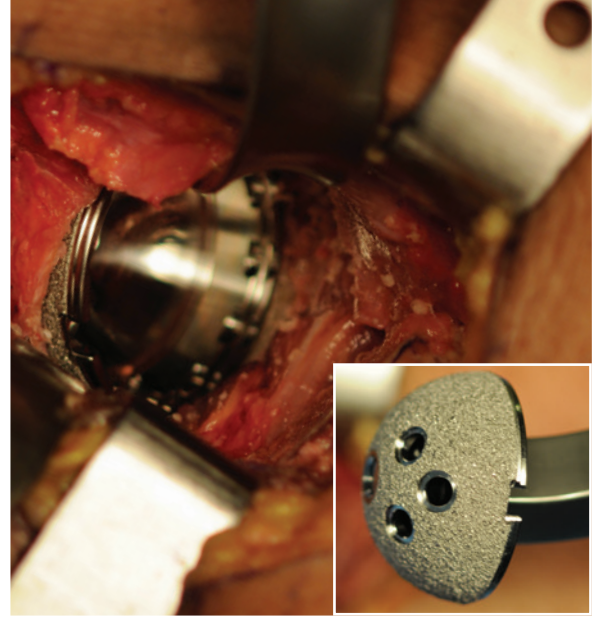




7 Acetabular reaming

An angled offset reamer is helpful when trying to achieve the desired level of adduction. Relaxation of the retractors can assist with reamer placement as well as clearing the acetabular rim of any soft tissue or exposed osteophytes. Begin reaming approximately 6 sizes smaller than the preoperative templated cup size.

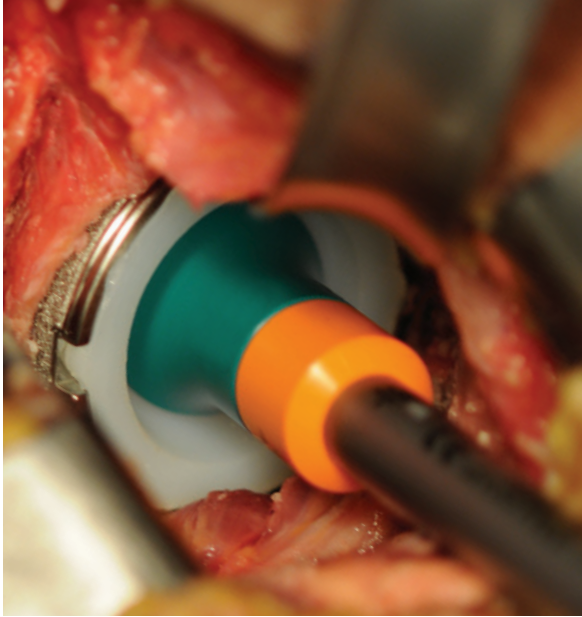
Surgeon tip For the R3° Acetabular System, ream line-to-line and check the last reamer under fluoroscopy if desired.



8 Cup impaction

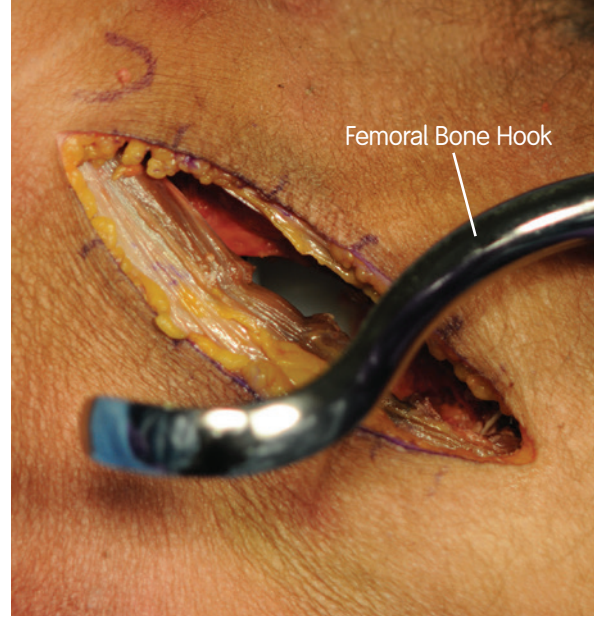
Remove the medial retractor to avoid lateralization of the implant and confirm initial position by using fluoroscopy intraoperatively. Insert the acetabular cup using the anterior wall as a guide. Impact the acetabular cup into place. Place screws in cup, if needed. After the cup is impacted, remove all traction on the femur.

Surgeon tip The offset cup impactor is useful when impacting the R3 Acetabular Cup. Ensure that the liner removal slot is proximal for accessibility in the event that the liner needs to be removed.



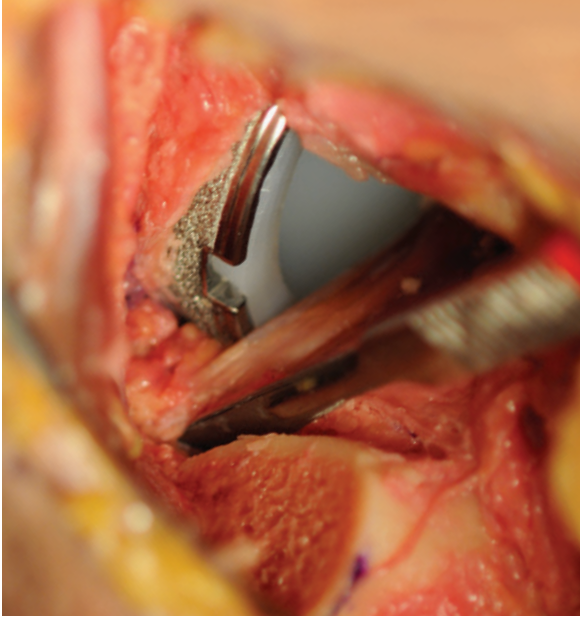
9 Liner insertion

Insert the appropriate acetabular liner into the shell by hand. Align the tabs to the shell ensuring no soft tissue is overhanging the cup and impact the liner into the shell.

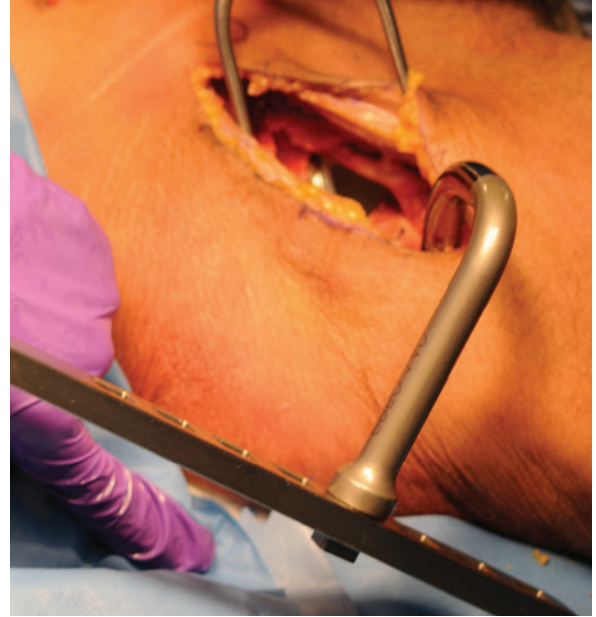

10 Femoral preparation

To achieve femoral exposure, remove the Charnley retractor and release all traction on the leg. Place the femoral hook, external to the vastus lateralis and proximal to the gluteus maximus tendon. (Do not engage the hook to the lift yet.)

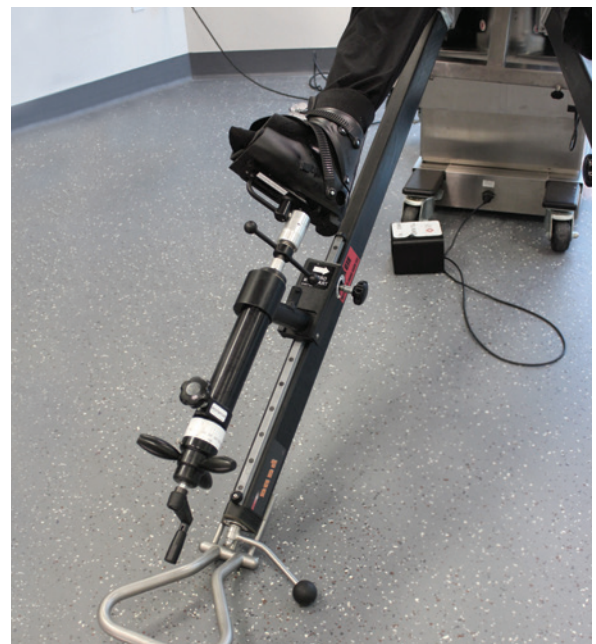

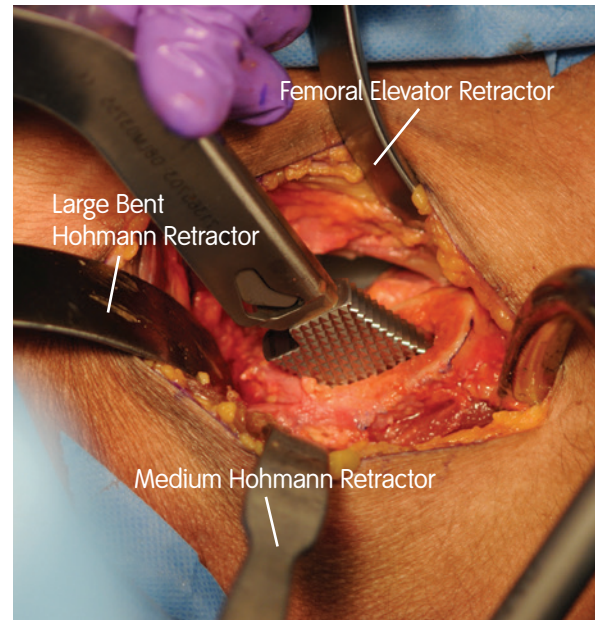
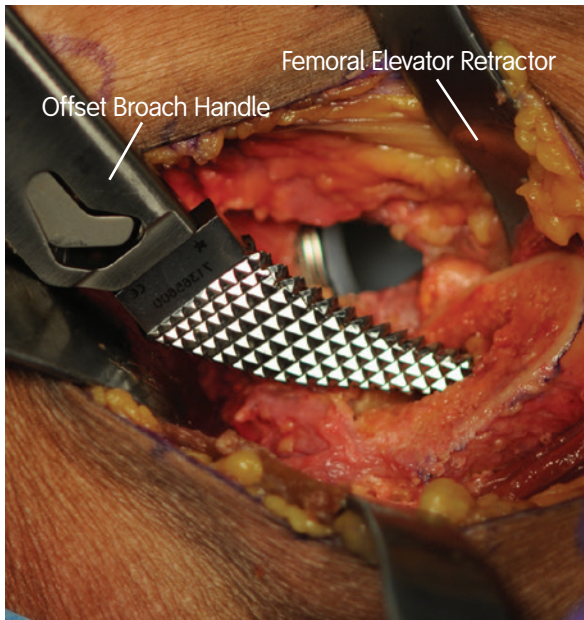
Externally rotate the femur 120° and place a sharp Hohman posterior to the neck, medially. Apply lateral traction to the hook by manual tension. Ensure that the femur distracts laterally, 1cm from the acetabular wall. If needed, extend the posterior capsulotomy and release the obturator internus. Extend the hip to the floor and engage the hook into the lift. Elevate the hook to hold the femur, only matching what could be achieved manually.



Place the trochanteric retractor through the superior capsule and over the trochanter and adduct the leg. Resect any remaining lateral femoral neck using a rongeur.

Note Any time the hip is in extension, traction should be removed from the operative leg to avoid injury to the femoral nerve and vascular structures anterior to the hip joint.



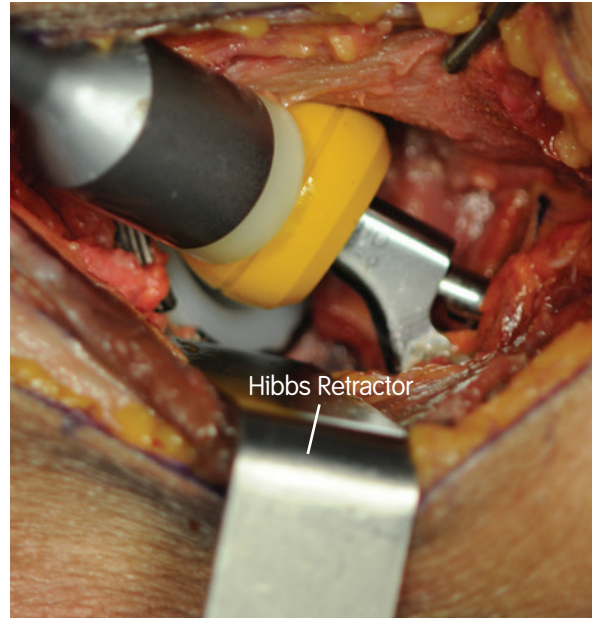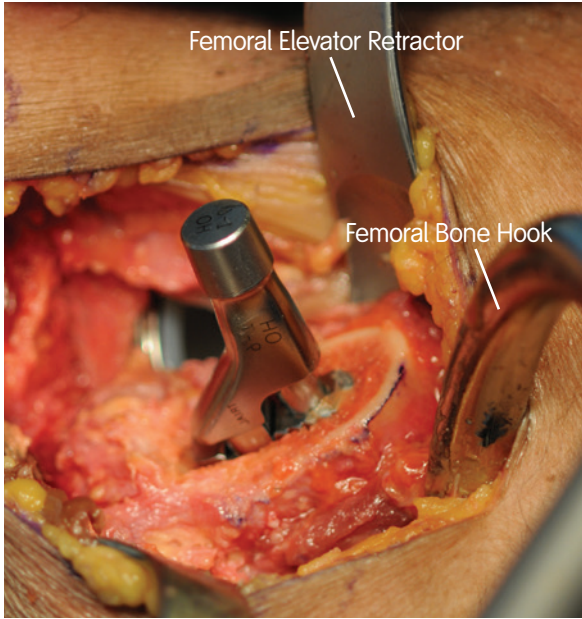


11 Femoral broaching

Once the femoral releases have been made and adequate femoral exposure has been attained, femoral broaching can begin. The femoral canal should be entered in the postero-lateral region to avoid varus alignment and stem undersizing. This can be achieved by using a box osteotome, high speed burr, or the starter broach. The starting ANTHOLOGY[®] broach is purposefully short to gain entry into the femoral canal without perforating the lateral femoral cortex, as could happen, if the broach was placed in extreme varus.

To ensure proper alignment, the number 1 broach can be checked under fluroscopy. Keeping rotation constant, progress upward in size until the desired preoperative templated broach size is attained. A long curette can be used, laterally to remove cancellous bone and lateralize the stem, if needed.

Surgeon tip If at any time during broaching the broach feels tight before reaching the desired template size, remove lateral bone from the trochanter, using a rongeur, high speed burr or long handled curette. Failure to remove this bone can lead to varus stem placement and/or trochanteric fracture.



12 Trialing/stability testing

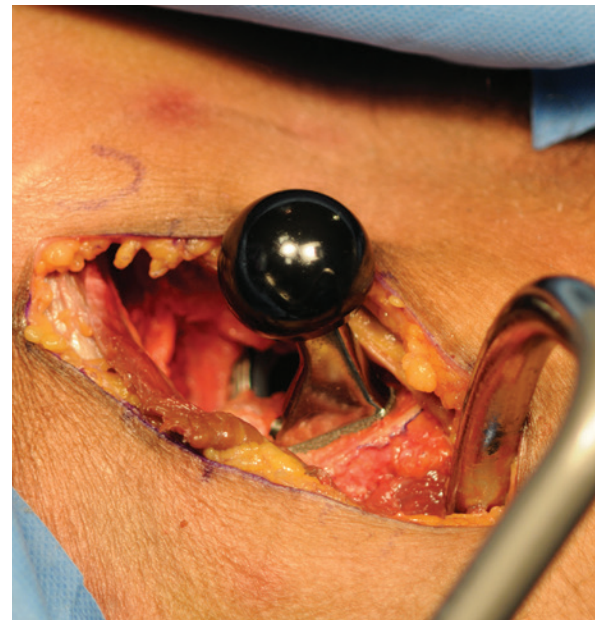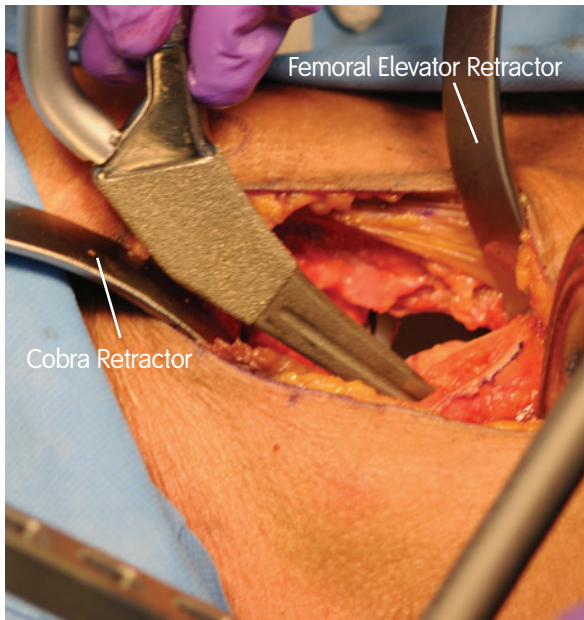
Place the modular trial neck and femoral head onto the final broach size. Remove all retractors and femoral hook and bring the hip back into neutral alignment with no traction placed across the femur. Externally rotate the leg to 100°, elevated through the leg sparr. Do not leave the leg in extension as reduction will be more difficult. Bring the contralateral leg to neutral alignment for leg length comparisons using fluoroscopy.

Place traction on the femur to bring the femoral trial head back into position. With traction on the femur, internally rotate the femur to deliver the femoral trial head into the acetabulum. Use fluoroscopy to evaluate the obturator foramen, observing if they are symmetric. If they are symmetric, denote any rotation of the pelvis. Image the operative hip again to evaluate the greater trochanter and its relationship to the ischium as well as the femoral head and broach size.

Surgeon tip: Following trial reduction, anterior stability can be assessed with the hip in neutral extension and 90 degrees of external rotation.

Posterior stability can be assessed by removing the boot from the leg sparr and placing the hip in 90 degrees of flexion, neutral abduction, and internal rotation of 60 degrees. The boot is then placed back into the leg sparr in neutral position.

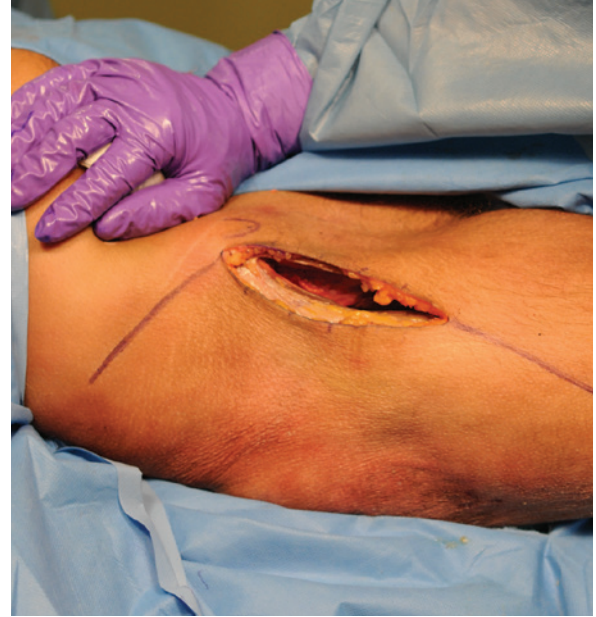
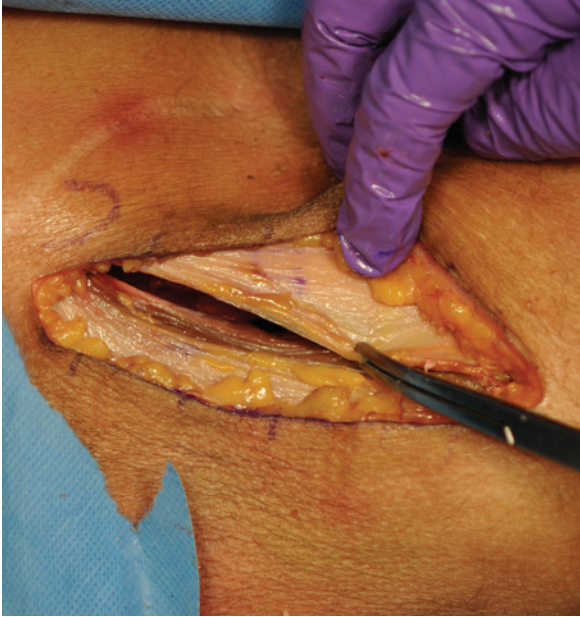


13 Stem implantation

Place the stem into the femoral canal using an inserter, or by hand. When fitted properly, the ANTHOLOGY[®] stem should sit within approximately 1cm of its desired depth based on preoperative templating. The offset insertion handle can then be used to fully seat the stem.

Surgeon tip Prior to final insertion, ensure that the insertion handle is not impinging on the greater trochanter. Failure to recognize this impingement may lead to varus stem placement or trochanteric fracture.



14 Closure

Repair capsulotomy using a number one running vicryl suture. Close the tensor fascia using a number one running/locking closure. A 2-0 vicryl subcutaneous/monocryl or nylon skin is then used to close the subcutaneous layer. A 4-0 monocryl subcuticular running closure and topical skin adhesive are used for final closure.

Surgeon tip A superficial drain can be used if the patient is obese.

Additional maneuvers

Comprehensive pelvic plating and distal femoral fractures can be considered through the Direct Anterior approach. If necessary, the original incision can be extended in order to gain better access to the femur. Proximally, the incision can be extended into a formal iliofemoral approach. Distally, the incision can be extended down through the iliotibial band and posterior to the vastus lateralis muscle for disaphyseal femoral exposure.

15 Postoperative measures

The patient should be weight bearing as tolerated with no dislocation precautions.

Catalog

Direct Anterior Retractor Set: 71365725

Catalog #	Description
71365554	Direct Anterior Retractor Tray
75100669	Posterior Retractor
75100668	Femoral Elevator
281630	Sharp Cobra
71934609	Large Bent Hohmann
71364031	Medium Hohmann
71364028	Blunt Cobra
71364032	Narrow Bent Hohmann
71365551	Bone Hook
71930020	Femoral Head Elevator

Implant constructs

ANTHOLOGY[®] Femoral Stems

Femoral Heads	Taper Sleeves
Cobalt Chrome 12/14 Femoral Head	Titanium Modular 12/14 Taper Sleeves
Cobalt Chrome Modular Femoral Head	TANDEM Titanium 12/14 Unipolar Sleeves
OXINIUM [®] 12/14 Femoral Head	
OXINIUM Modular Femoral Head	
BILOX [®] Delta 12/14 Femoral Head	
TANDEM [®] Unipolar OXINIUM Femoral Head	
TANDEM Unipolar CoCr Femoral Head	

For use with Smith & Nephew 12/14 femoral heads only.

Products may not be available in all markets because product availability is subject to the regulatory and/or medical practices in individual markets. Please contact your Smith & Nephew representative or distributor if you have questions about the availability of Smith & Nephew products in your area.

Smith & Nephew, Inc.
7135 Goodlett Farms Pkwy
Cordova, TN 38016
USA

www.smith-nephew.com

Telephone 1-901-396-2121
Information 1-800-821-5700
Orders/inquiries 1-800-238-7538

[†]Trademark of Smith & Nephew.
All Trademarks acknowledged.

©2023 Smith & Nephew, Inc.
All rights reserved.
28379 V3 71381619 REV 04/23